

REVIEWS

Adv Clin Exp Med 2014, 23, 4, 645–655
ISSN 1899–5276

© Copyright by Wrocław Medical University

URSZULA ZALESKA-DOROBISZ^{A, D, F}, KRZYSZTOF KACZOROWSKI^{B, D-E},
ALEKSANDER PAWLUS^{B, D-E}, AGATA PUCHALSKA^{B, D-E}, MARCIN INGLOT^{B, D-E}

Ultrasound Elastography – Review of Techniques and its Clinical Applications

Department of Radiology, Wrocław Medical University, Poland

A – research concept and design; B – collection and/or assembly of data; C – data analysis and interpretation; D – writing the article; E – critical revision of the article; F – final approval of article; G – other

Abstract

Sonoelastography is a modern ultrasound method, which enables the representation of tissues and organs with the evaluation of their elasticity, “stiffness”. The principle of elastography is to use repeated, slight pressure on the examined organ with the ultrasound transducer. Changes in elasticity and deformation of tissues arising whilst the compression is processed and presented in real time with color-coded maps, is called elastograms. The method is applicable mainly in diagnosing malignant lesions. Tumor tissues have different elasticity and undergo different deformations under pressure than healthy tissues. As a result of computer analysis, images in various colors are generated. Based on the nature of areas of normal and increased stiffness classifications of the images in point scales have been developed. Ultrasound devices equipped with sonoelastography option enable more accurate imaging and evaluation of the nature of lesions situated at small depth, e.g. breast, thyroid, testicles, prostate, some groups of lymph nodes. They increase the accuracy of ultrasound in diagnostics and the evaluation of the stage of malignant lesions. This also helps to indicate more precisely the areas that require the biopsy (*Adv Clin Exp Med* 2014, 23, 4, 645–655).

Key words: sonoelastography, ultrasound, diagnostic imaging.

Ultrasound elastography (sonoelastography) is a noninvasive imaging technique that can be used in medicine to define stiffness of the tissues or displacement (strain) in response to an applied force [1–3]. The elastographic examination looks almost identical to a regular ultrasound examination [3, 4]. The usefulness of this method is based on the fact that pathological changes in tissues generally affect also in their stiffness [2–5].

An acquired image (elastogram) is not the result per se. It requires the physician’s analysis during the examination and after it. Principles of sonoelastography are based on using repeated pressure of the ultrasound probe on the tissue. Differences in tissue displacement are calculated and presented as color maps, so-called elastograms [2, 3, 6–8]. An innovative technique allows lapping that color scale with an elasticity score over the regular grey-scaled ultrasound image. Each elasticity score is coded by a different color [5, 8]. The range of colors, from

red to blue, corresponds to increasing stiffness of the tissue of interest. Red color represents soft tissues, green those of intermediate stiffness and blue “hard” ones. Color-scaled elastograms lapped over the grey-scaled sonograms allow for an analysis of elasticity of noticed lesion.

Interpretation of acquired images is usually based on a comparison the areas of different cohesion to standardized scales, e.g. Tsukuba scale, which helps to number noticed lesion among the group more or less suspected of malignancy [7, 8]. Many malignant changes, like cancers of the breast or prostate, appear as lesions of higher stiffness [1–5, 7]. In scientific research, it is generally agreed that no other physical parameter of tissue is changed by pathological or physiological process so remarkably as its elasticity [3, 4, 8, 9]. Since the late eighties, investigators aimed to provide images that showed elastic differences in organs [3, 4, 9].

The majority of malignant lesions is less elastic

– it does not undergo displacement in comparison to its surrounding tissues. This feature is characteristic for malignant tumors, e.g. tumors of breasts, thyroid, liver or prostate. Sonoelastography allows us to find pathologically changed areas in organs that are not noticeable in a regular ultrasound examination. Data acquired in elastographic examination increases the chances of noticing early lesion (e.g. in prostate or breasts) and increases the possibility of its precise analysis.

Moreover, elastography is a useful tool to very precisely indicate the place of a possible biopsy by exposing areas potentially most pathologically changed [9, 10].

One of the first attempts of this was through research by Lerner et al. [1, 8]. He used low-frequency vibrations provided by an external source that was brought into close contact to the organ. Differences of amplitudes of peak vibration between hard lesion and soft homogeneous tissue were mapped on a gray scale. However, the term “elastography” was introduced by Ophir et al. to describe their ultrasonic elasticity-imaging approach [1–3, 6, 7].

Sonoelastography is a new technique, first described in 1987 by Krouskop et al. [1, 3]. Since that moment, elastography has been utilized to evaluate numerous types of tissues, including liver, breasts, thyroid, lymph nodes, but also blood vessels, musculoskeletal structures, pancreas or even brain [6, 10–14].

In last two decades a couple ways of acquiring elastograms were developed and different methods of elastosonography were known, but imaging of elasticity of the human body is still being evaluated [3, 4, 7, 11, 12, 14].

Review

Principles of Ultrasound Elastography

Elastosonography provides knowledge about internal strains induced in a soft material undergoing an axial stress [2, 5, 8–10]. There is a proportional relationship for many solids between the measured strain and the load over a wide range of loads. It is a linear relationship described by Hooke’s law, which says that every component of the state of stress at a point is a linear function of the components of the state of strain at the point (Saada 1989). This can be presented as a mathematical equation:

$$\sigma_{ij} = C_{ijmn} \varepsilon_{mn} \quad \{i, j, m, n = 1, 2, 3\},$$

where C_{ijmn} are elastic constants comprising the elements of a stiffness matrix and σ_{ij} is the stress

component in a plane perpendicular to the axis x_i and parallel to the axis x_j .

The biological tissue behavior in elastography is assumed to be linear elastic for small deformations, isotropic and nearly incompressible. Considering this, the equation can be expressed by using two independent parameters known as the Lamé’s constants λ and μ :

$$C_{1122} = \lambda$$

$$C_{1111} = \lambda + 2\mu$$

$$C_{1212} = \frac{1}{2}(C_{1111} - C_{1122}) = \mu$$

The constant μ , is referred to as the shear modulus. The volume change per unit volume due to spherical stress is dependent on the bulk compressional modulus K , which is related to the Lamé’s constants by:

$$K = \frac{(3\lambda + 2\mu)}{3}$$

Two other parameters are used to represent mechanical properties of solid tissues: Young’s modulus, E , and Poisson’s ratio, ν . These are connected to K and μ by the leading expressions [3, 8, 11, 12]:

$$K = \frac{E}{3(1 - 2\nu)}$$

and

$$\mu = \frac{E}{2(1 + \nu)}$$

However, most tissues have properties intermediate between solid bodies and fluids. Furthermore, soft tissues share with liquids are nearly incompressible and also its density differs little from that of water. These facts explain mechanical behavior of soft tissues, which can be anisotropic, non-Hookean and viscoelastic [2, 3, 11, 13, 14]. In fact, the linear elastic Hookean behavior can be used for elasticity analysis only for very small static deformations [2, 3, 5, 8].

In the past two decades there was much research aiming to characterize the mechanical properties of biological tissues such as the shear or elastic modulus (Young’s modulus), the Poisson’s ratio, or any of the longitudinal or shear strains that occur in tissues as a response to an applied load [1–3, 8]. An important fact is that there is no direct correlation between echogenicity and stiffness of the tissues and imaging tissue stiffness, or an associated parameter, such as a local tissue strain, may render new information which can be compared to sonograms [3, 8, 10, 11, 13, 14]. In general, sonoelastography techniques can be divided into three groups:

1) where components of displacement or of the strain tensor which are a result of a quasi-static compression applied to the tissue are estimated;

2) based on a monochromatic low-frequency vibration, for example, sonoelasticity, (Krouskop et al. 1987, Lerner et al. 1990, Yamakoshi et al. 1990) where Doppler signals are used to estimate tissue displacement and vibro-acoustography (Fatemi et al. 1998) in which ultrasound-stimulated acoustic emission is used [1–3, 5, 7];

3) based on properties of shear waves, such as Transient Elastography (TE) (Sandrin et al. 1999), Acoustic Radiation Force Impulse (ARFI), Shear-Wave Elastography [2, 3, 8, 10, 12, 15].

In the evaluation of elastograms, different scales are used, e.g. the five-point Tsukuba scale, proposed by Itoh A. et al., which represents the degree of deformation of the examined tissues using schematic patterns [3, 5].

Quasi-Static Elastography

Quasi-Static Elastography (QSE) is one of the most popular commercially available techniques. It is based on the compression of tissue by external mechanical force or an internal endogenous force [5, 7, 9]. During tissue deformation, several images are made. Displacement, motion and time delay between the local region of interest (ROI) within two subsequent images are recorded during different compression. A value for every pixel is calculated from two subsequent images. Because of the dependence of used mechanical force and surrounding tissue, this value is relative [2, 3, 7, 9]. Therefore, this is an example of qualitative elastography. The effects of the calculations for every pixel can be visualized on the screen in different ways: side-by-side to the conventional B-mode image or overlaid on the B-mode image. The quality of the examination depends significantly on the experience and technique of the investigator. First, he has to choose the right angle of compression. If it is not done correctly, artifacts leading to misinterpretation can occur. Secondly, it is important to apply adequate compression strength. The strength and duration of manually induced deformation should be visually controlled. The compression needs to be performed at least two times to make elastograms reproducible [3, 9]. Real-time ultrasound elastography has been recently developed. It is an example of semi-quantitative elastography as the software measures the ratio between nodule and normal parenchyma. However, it is still relative and does not give precise values of viscoelastic parameters [3, 5, 7, 9].

Vibro-Acoustography (VA)

This method uses the acoustic response (acoustic emission) of a tissue to the harmonic radiation force of ultrasound for imaging and material

characterization [2, 3, 8, 9]. Acoustic emission is generated by focusing two ultrasound beams of slightly different frequencies at the same point and vibrating the tissue. Vibrations of tissues are a consequence of ultrasound radiation force used on the object at a frequency equal to the difference between the frequencies of the primary ultrasound beams. The radiation force from these two beams has a component at Δf (called dynamic ultrasound radiation force), which vibrates the object. A hydrophone detects the acoustic response of the tissue to this force. The acoustic signal is recorded as a result of raster scanning across the object the co-focus of the ultrasound beam. The brightness of each image pixel proportional to the amplitude of the acoustic signal from the excitation point of the object is modulated to form an image of the object [8, 9]. Although VA is basically an imaging method there are attempts to use it to provide quantitative estimations of viscoelastic parameters [3, 7, 9].

Transient Elastography

Transient Elastography (TE) was originally a one-dimensional method which gives a single elasticity value from a region [3, 10]. In this method both ultrasounds and low-frequency (50 Hz) mechanically generated shear waves are used. Propagation speed of shear waves is directly related to the elasticity of tissues. This propagation is slower in soft tissue than in a stiff region [3, 6, 10, 11, 15, 16]. Transient Elastography is example of a quantitative method [3, 6, 8, 10, 16, 17, 19, 20]. This method is used in a machine developed by Echosens commercially available as FibroScan®. Despite original one-dimensional character of TE, a two-dimensional variation has been developed [3, 10, 16, 17, 19, 20]. General limitations of TE are:

- 1) ability to explore only the low volume of parenchyma,
- 2) measurement guiding is impossible due to the absence of ultrasound imaging,
- 3) possible difficulties in measurement in case of obesity or ascites,
- 4) the lack of specificity for the distinction of significant fibrosis level,
- 5) lack of imaging guidance making this method difficult to learn.

Acoustic Radiation Force Impulse (ARFI)

ARFI gives not only elastograms but also sets some parameters of soft tissue like peak displacement, the time that it takes to reach peak

displacement, and the recovery time. Due to this fact it can be found as quantitative elastography [3, 16, 17, 20]. It is based on the mechanical excitation of tissue by providing localized, impulsive, acoustic radiation force, so that shear wave propagates away from the region of excitation [17, 20]. Tissue response for displacement induced by excitation is measured and used to generate elastogram [17, 19–21]. ARFI is a one-dimensional technique and has some limitations such as: inability to provide an elasticity map of tissue or to perform elasticity measurement retrospectively. In addition, these measurements are not in real time, there is no information about standard deviation, only the average value is calculated in the ROI. Also, the possible depth of the ROI is reduced due to the frequency limitation caused by excessive transducer heating [7, 17, 20, 21].

Shear Wave Elasticity Imaging (SWEI) and Supersonic Elasticity Imaging (SSI)

These methods are based on measuring shear wave propagation velocity in soft tissue [3, 7, 9, 12, 22, 23]. The ultrasound probe generates a very localized radiation force, which induces shear waves that propagate from that focal point directly in the tissue of interest. A subsequent change in the depth of focal location leads to interference of shear waves and the generation of a conical shear wave. These are principles of SSI [3, 22–24]. This technique requires very fast acquisition of ultrasound images, at least 5000 frames per second up to 20000 frames per second [7, 20, 23, 24]. Such fast acquisition reduces the risk of artifacts made by patient or investigator movements. SSI make it possible to create a two-dimensional color map, where color codes speed of wave in meters per second or elasticity of the tissue in kilopascals. This real-time imaging method is also an example of quantitative elastography [3, 9, 6, 7, 11]. SWEI and SSI have limits on the intensity used to avoid both mechanical and thermal bio-effects so it may cause difficulties in analyzing deeper-located tissues.

Other Methods

There are some variations of sonoelastography that need to be mentioned. The first is endoscopic ultrasound elastography and trans-rectal ultrasound elastography [3, 12–14, 25]. There are promising reports about its high specificity in diagnosing e.g. malignancy in lymph nodes and pancreatic cancer [13] or diagnosing inflammatory bowel

diseases [11, 25]. The second is Intravascular Ultrasound Elastography (IVUSE) [24]. Despite that technique being still in its infancy, it could substantially improve the differential of atheromatous plaques [14]. The third is three-dimensional shear wave elastography (3D SWE). Recent research did not show the superiority to the two-dimensional shear wave elastography (2D SWE) combined with B-mode ultrasound in differentiating breast lesions; however, there are some unique features, like more reproducibility, of 3D SWE that allow us to set hopes on this method [11, 19, 20, 22, 23].

Clinical Use of Elastosonography

Breast

Another common application of US elastography are breast examinations [1, 4, 25, 26]. This issue has been studied systematically since 1997. Garra et al. [25] reported that US elastography has very good results in detecting tumors and distinguishing cancerous lesions from benign ones.

Itoh et al. [26] found that elastography has diagnostic performance which is comparable to conventional US with 86% sensitivity, 90% specificity, and 88% accuracy for the differentiation of benign and malignant solid breast masses.

Zhi et al. [27] compared three methods – US elastography, conventional US and mammography.

Elastography was the most specific (95.7%) of the 3 modalities. The accuracy (88.2%) and positive predictive value (87.1%) of US elastography were higher than those of conventional US (respectively 72.6% and 52.5%). A combination of US elastography and conventional US had the best sensitivity (89.7%) and accuracy (93.9%) and the lowest false-negative rate (9.2%). The specificity (95.7%) and positive predictive value (89.7%) of the combination were better, and the false-positive rate (4.3%) of the combination was lower than those of mammography and sonography. In consequence, using elastography as an adjunct to routine breast ultrasound could potentially reduce unnecessary biopsies. This seems to be an important aim because nearly 80% of biopsied breast lesions turn out to be benign, according to the American Cancer Society [4, 11, 25, 26].

Another significant issue is to evaluate the criteria for breast masses classification in elastography which should help to improve the consistency of the diagnosis. Several diagnostic criteria have been proposed, which include lesion visualization, relative brightness, margin regularity, and lesion

size in comparison with B-mode US images [25]. It was also noted that cancerous lesions appear larger on the elastogram than they do on the corresponding sonogram. Stromal response to breast cancer causes myofibroblasts to produce collagen and extracellular matrix proteins, which increases the stiffness of the tumors and the tissues surrounding them. The strain difference, which is used as a means of producing contrast in elastography, causes the measured transverse diameters of malignant tumors on elastograms to be larger than those measured in conventional US images. The combination of lesion stiffness and size relative to the sonogram results in the possibility to distinguish benign from malignant lesions and allows for more precise mapping of tumors [4, 5, 11, 27].

Liver

One of the most common applications of US elastography imaging is the evaluation of hepatic cirrhosis, fibrosis [3, 4, 10, 11, 15–19] and focal liver lesions [17, 23, 24].

In patients with chronic liver diseases, determination of inflammation grading and fibrosis staging is important for prognostic reasons and for identifying patients who will benefit from the treatment [4, 19]. Assessment of liver fibrosis can also determine the response to treatment in patients already receiving treatment. Following not only the progression, but also the regression of fibrosis over time could be very important, because research has demonstrated a reduction in liver fibrosis with treatment, even in advanced stages

[10, 16, 18–21]. Hepatocellular carcinoma screening can also be implemented for patients identified with underlying cirrhosis [4, 10, 17].

At present, liver biopsy still remains the gold standard in the evaluation of liver fibrosis [20–22]. The accuracy of this method is, however, limited by the specimen size and fragmentation, sampling error, and inter-observer variability [20–24]. Furthermore, it is an invasive, painful and relatively expensive procedure, which can be associated with significant morbidity and, rarely mortality, rendering it less acceptable by patients and clinicians [24].

Therefore, a new non-invasive technique of hepatic fibrosis evaluation was an important aim of research. One of the available methods is based on the measurement of fibrosis serum biomarkers, and the second takes advantage of liver stiffness measurement. Using a combination of different blood marker levels and the assessment of tissue elasticity based on elastography has shown promising results in the determination of the degree of liver fibrosis [9, 10, 23, 24].

It was demonstrated that liver stiffness and viscosity increase with the degree of fibrosis up to the level of cirrhosis [7, 9, 10, 23]. Recently, several elasticity imaging techniques have been developed for the assessment of the mechanical properties of liver tissues and fibrosis staging (Fig. 1). Different imaging modalities, such as magnetic resonance elastography, transient ultrasound elastography (TE), supersonic shear imaging (SSI), shear wave dispersion ultrasound vibrometry (SDUV) and a few others were used [4, 5, 19, 20].

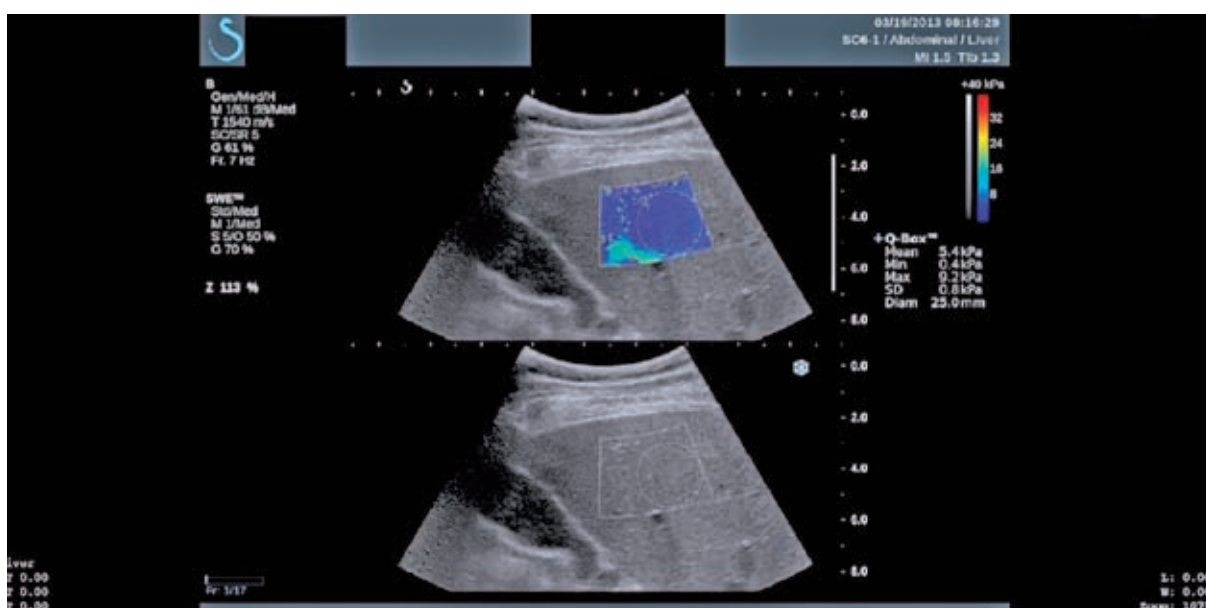


Fig. 1. Shear Wave elastography – dynamic real-time elastography of the liver of patient with 7-year history of Hepatitis C. Measured value of liver stiffness is 5.4 kPa, which indicates stage F0 of liver fibrosis

In the past few years, transient elastography (TE), implemented in the FibroScan[®] machine, has been increasingly used as a liver fibrosis assessment tool [18, 21, 24]. In this technique, the probe consists of an ultrasound transducer, which is located at the end of a vibrating piston. The transducer generates a mild amplitude and low frequency vibrations that induct elastic shear wave that propagates through the underlying tissues. The propagation of the shear wave through the liver is detected by an ultrasound probe. The software automatically calculates the velocity of shear wave propagation. Higher velocity is related to higher tissue stiffness that corresponds with the stage of fibrosis. The test is performed with the patient lying in the supine position, with the probe placed at the intercostal space overlying the liver [9, 10, 22, 24].

The advantages of transient elastography are that the procedure is painless, rapid and easy to perform and the results are available immediately. Transient elastography has been shown to be highly reproducible with minimal inter- and intra-observer variability. The range of possible liver stiffness values obtained with transient elastography is from 2.5 to 75.0 kPa, with the normal liver stiffness value for healthy individuals being around 5.5 kPa [22–24]. In METAVIR liver fibrosis stage scale optimal stiffness cutoff values of 8.7 and 14.5 kPa showed respectively $F > \text{or} = 2$ and $F = 4$ [5, 20].

It is worth mentioning that elastography can be an alternative method for the patients with absolute or relative contraindications against the liver biopsy which include *inter alia* the absence of patient cooperation, clotting abnormalities, morbid obesity or ascites [3, 4, 10, 20, 21].

Another method that can be used to assess liver fibrosis is Shear Wave Elastography – SWE available in Aixplorer machine. Like TE, SWE estimates the propagation speed of a shear wave to measure tissue stiffness. The color elasticity map is overlaid on a traditional b-mode ultrasound image. It is possible to change the size and position of the elasticity map. When the image is frozen the circular ROI can be set to measure the average stiffness and SD within the ROI. Additionally, while using SWE system, it is possible to examine liver anatomy in real-time and to choose the best place to measure tissue stiffness. The combination of both SWE and traditional B mode imagining can result in a more accurate staging of liver fibrosis. There are several studies demonstrating the high accuracy of SWE in the assessment of liver fibrosis [16, 17, 20–22].

Elastography methods have also been used to determine focal liver lesions [10, 16, 17, 20]. One of the main courses of research is hepatocellular carcinoma (HCC) detection and differentiation from other lesions. HCC lesions are typically

harder than normal liver tissue. Although this difference may be less pronounced when compared to cirrhotic liver in which the tumors typically occur. Ultrasound elastography seems to be a promising procedure to predict the risk of hepatocellular carcinoma [15, 17, 24]. However, further studies are needed to confirm the usefulness of this method.

Thyroid

Nowadays, the most important examination of thyroid structure is ultrasonography with B-mode and Doppler [6, 7, 10, 15, 26, 27]. It gives a lot information about the echogenicity of parenchyma, presence of nodule, blood flow etc. However, information about nodules is often inadequate. The majority of thyroid nodules is benign, but it is not always possible to exclude its malignancy only by using ultrasonography (Fig. 2). Fine-needle aspiration cytology (FNAC) is the main tool to define character of nodule due to its accuracy and reproducibility [6, 28–30]. However, FNAC is characterized by a grey diagnostic area – Thy3 in the British Thyroid Association guidelines [4, 29, 30]. The consequence of this fact is that about 80% patients with Thy3 undergo unnecessary thyroidectomy [30, 31]. Elastography is considered as a technique that combined with ultrasonography will improve basic diagnosis of thyroid, accuracy of FNAC or even will substitute FNAC [31].

Quasi-static elastography gives only qualitative or semi-quantitative information about elasticity of the tissue. Therefore, the term of strain ratio (or elasticity score) is in use. Generally, the value of those parameters depends on the difference between the stiffness of the nodule and normal parenchyma. Ratio of 4 allows to us to consider a lesion as hard nodule (Fig. 3). However, in the research there were used different cutoffs [10, 27, 31, 32]. Results of the research were ambiguous. First results were encouraging [6, 26]. For example, a meta-analysis published in 2010 showed that qualitative real-time ultrasound elastography has a sensitivity of 92% specificity of 95% in differentiating malignant to benign nodules and it could reduce unnecessary surgical interventions after FNAC [28, 29]. However, later research did not confirm the usefulness of USE in the pre-surgical selection of nodules and suggests the need for a quantitative or semi quantitative elastography [6, 26, 27, 30]. A study from Sapienza University of Rome reported high sensitivity and specificity values Q-elastography in the differential diagnosis of thyroid nodules with indeterminate cytology [4, 32].

SWE gives precise information about tissue stiffness in kilopascals [10, 31]. Moreover, this

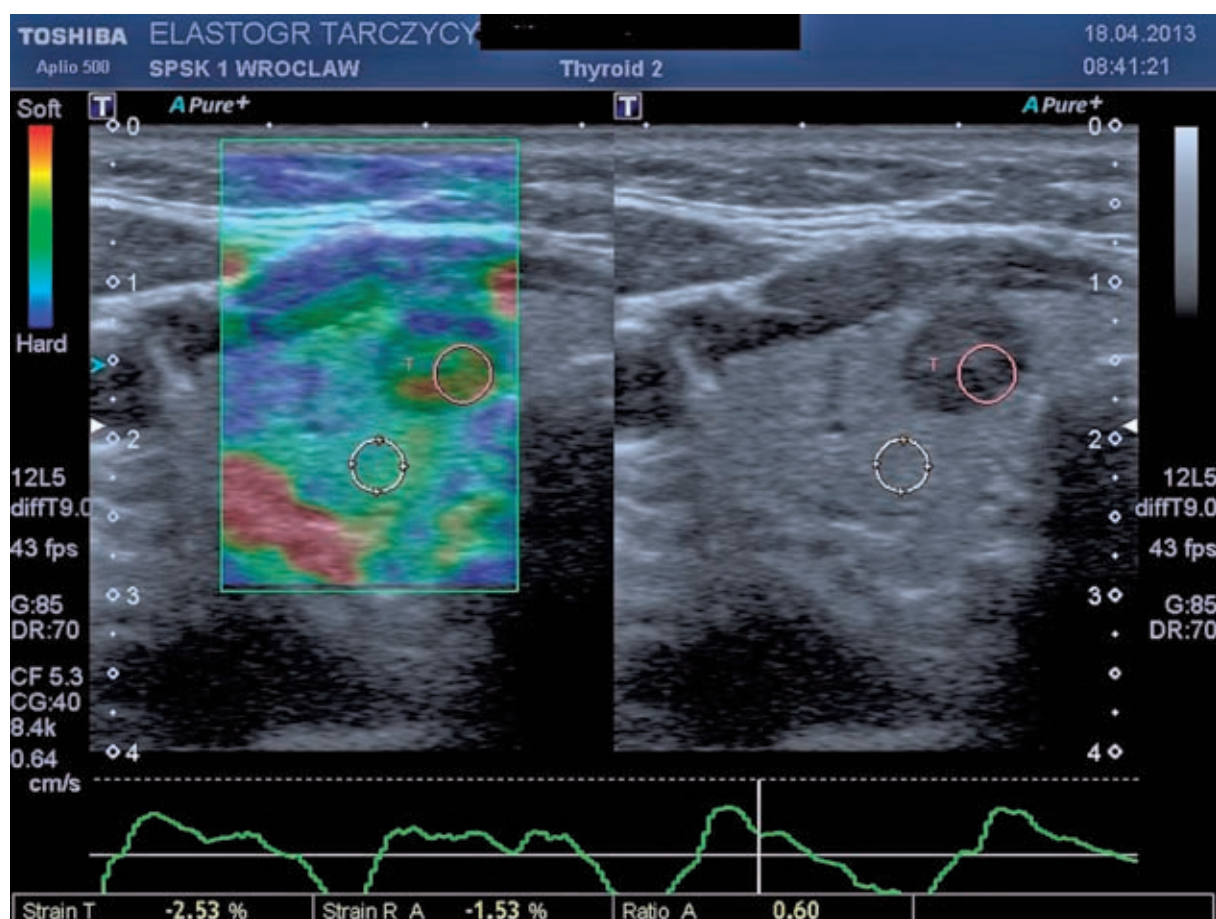


Fig. 2. Thyroid, B-mode with static elastography – lesion of low stiffness, B-mode image reveals lesion with high suspicion of malignancy, elastography indicates benign character of lesion due to low strain ratio. Follow-up confirmed adenoma

method is considered not to be as dependent on examination techniques as quasi-static elastography due to the lack of the necessity to compress the tissue [30, 31]. However, the results of research estimating diagnostic utility of SWE in differentiating malignant to benign nodules are also equivocal. Probably the largest study in the last years gave unsatisfactory results [9, 10, 30, 31] in comparison to the first encouraging research. A study by Sebag et al. showed a sensitivity of 85.2% and a specificity of 93.9% by using the cutoff value of 65 kPa [9, 31]. Later research by Kunwar et al. reported a sensitivity of 76.9% and specificity of 71.1% by using the cutoff value of 34.5 kPa, which was the threshold of highest accuracy [6]. That study showed that SWE is probably more operator-dependent than it was considered to be. Furthermore, the meaningful role of factors that may impact SWE is mentioned, such as the possibility of compression artifacts in the superficial fascia, vertical artefacts on SWE and areas devoid of SWE signal in some solid nodules [9, 10]. The conclusion is that further studies are necessary, especially when some technical limitations of SWE will be solved [3, 6, 29–31].

Another issue is the possibility of using elastography to diagnose diffuse diseases of thyroid. There are some studies performed to estimate the value of elastography in such cases. In fact, only quantitative or semi quantitative techniques are likely to be useful. There is research that confirmed the possibility of measuring the increased stiffness in Hashimoto disease by using MRE [4, 6] and studies that reported possible usefulness of ARFI to confirm the presence of Graves' disease and chronic autoimmune thyroiditis [6, 27, 28, 32]. However, it is not clear if all types of thyroiditis can be detected or distinguished by using quantitative elastography [27, 29–32].

Lymph Nodes

Elastography of the lymph nodes was used first by Janssen et al. [33]. He examined 50 patients using elastography and needle aspiration biopsy [33]. The examination was carried by two independent specialists. Lymph nodes of posterior mediastinum were examined. 66 lymph nodes were assessed. The examination showed that 37 were normal and 29

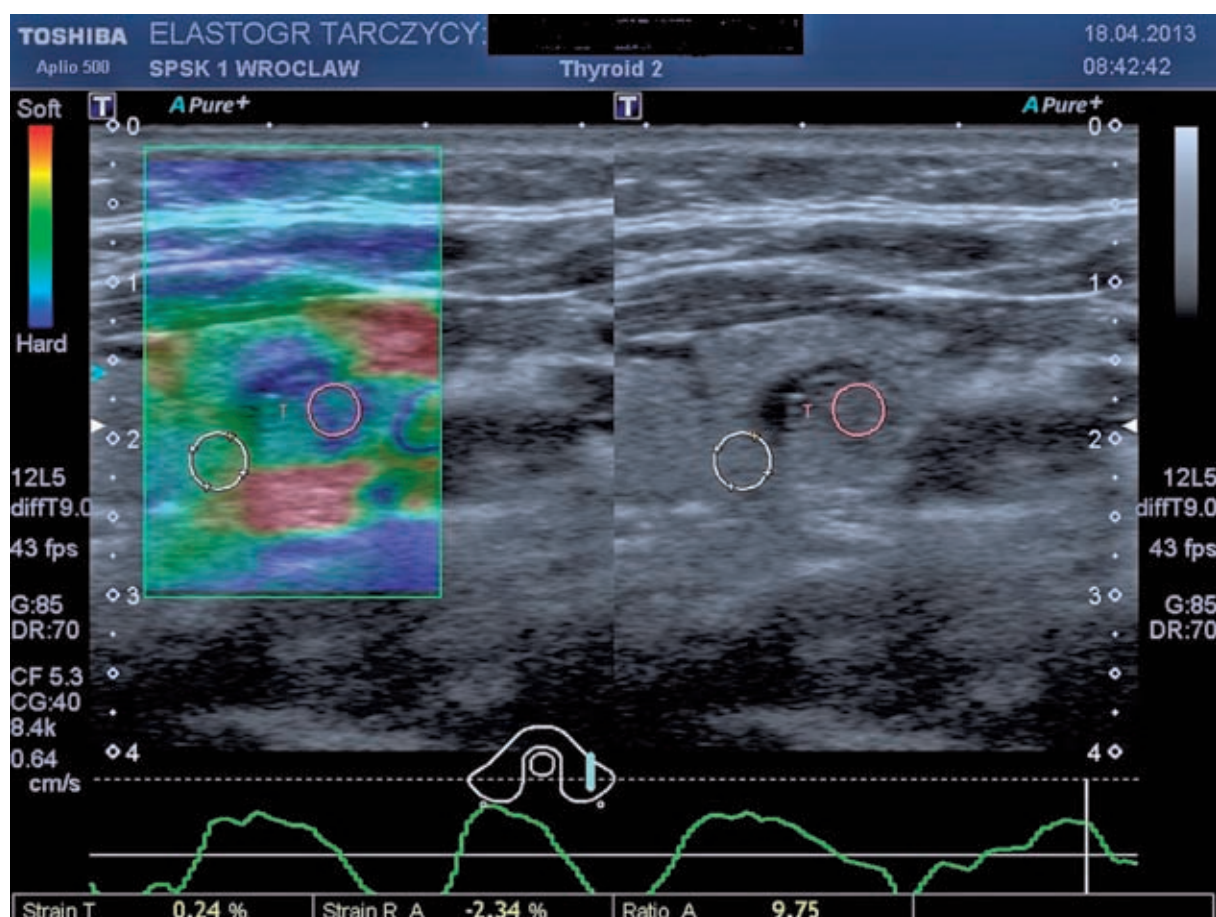


Fig. 3. Static elastography of thyroid- hetero-, hypoechoic lesion of high stiffness. Follow-up confirmed carcinoma papillare

were malignant. The examination of 31 out of 37 normal lymph nodes showed a homogenous elasticity pattern, while malignant lymph nodes were described as hard heterogeneous lesions. The compatibility factor between specialists was very high and it was $k = 0.84$. The examination of normal lymph nodes was confirmed in 81.8–87.9%, in the case of malignant lymph nodes the conformity was 84.6–86.4%.

The other report [33–35] shows that the cortex of the lymph node in elastography examination is harder than the cortex of both normal lymph nodes and those with metastases. The cortices of normal and those with metastases lymph nodes do not exhibit the difference in elasticity but the cortex of malignant lymph nodes was much harder. Scientist compared the specificity of various diagnostic methods: clinical trial – 13.3%, ultrasonography B mode – 40%, Doppler ultrasonography – 14.3%, elastography – 60% and the specificity was respectively: 88.4%, 96%, 95.6%, 79.6% [34, 35]. The assessment of the lymph nodes in elastography was done by means of a five-level scale of colors: red, yellow, green, turquoise, blue. Lyshchik et al. used a four-level scale of colors [33].

They examined 64 axillary lymph nodes. Their calculation was based on the percentage share of high elasticity areas (hard blue). The specificity of the method was estimated as 80.7% and the specificity as 66.7%. Saftiou et al. examined 42 cervical, mediastinal and abdominal lymph nodes by the usage of endoscopic elastography. Method sensitivity was 91.7% and the specificity 94.4%. A new method to assess elastograms was used by [36]. It takes into consideration, visibility, relative brightness, margins regularity, margins of definition. They examined 141 patients and described the specificity as 98%, the method's sensitivity as 85% and conformity as 92%. In literature there are other reports which assess the specificity and method sensitivity: Giovannini et al. [13] examined 31 cervical and mediastinal lymph nodes as well as para-aortic lymph nodes in the size of around 20 mm. The specificity of sonoelastography was presented as 100% and specificity as 50%. The examination which was carried in more numerous group of patients (101) using needle aspiration biopsy, US, EUS allowed to differentiate malignant and benign lesions with the specificity of 82.5% and sensitivity of 91.8%. The elastography of the lymph nodes

is a very good method which assists needle aspiration biopsy of lymph nodes. Thanks to this method the specificity of the examination is bigger and at the same time the number of complications is smaller [3, 5, 35, 36].

Prostate Gland

The prostate gland was first examined by elastography [2–4, 7]. This method is constantly being improved and it allows us to show the lesions which are in the prostate gland. It helps in making a decision on whether to carry out a biopsy and thanks to higher precision additional contuses is not necessary. In a normal ultrasonography examination (B-mode US) prostatic carcinomas are hypoechogenic, some are isoechogenic and some, very rarely, hyperechogenic. The sensitivity of traditional ultrasonography examination is assessed as 50% [34, 37]. Ultrasonography examination additionally with Doppler increased the method sensitivity, but only by 5%. According to Kamoi [3, 4] in elastography of prostate gland the sensitivity is 76%. Zhang et al. [40] noticed that prostatic carcinomas have a higher elasticity factor than normal tissue – the prostate gland is darker and more blue in elastogram. The other reports compare the effectiveness of this method with biopsy-proven prostatic carcinoma [38–40].

Trans-rectal elastography revealed carcinoma in 93% cases (27 patients). Detectability of carcinoma was higher than in TRUS (trans rectal US) – 59% in 16 patients. Junker et al. noticed that the effectiveness of sonoelastography of the prostate gland depends on malignant tumor size [40]. In the case of foci of 0–5 mm the effectiveness of this method is 6/62, 6–10 mm is 10/37, 11–20 mm is 24/34 and the highest detectability of 14/14 is in the case of tumors bigger than 20 mm. Pozzie et al. [36] examined 460 patients and they diagnosed in 32.17% biopsy-proven prostatic carcinoma. The authors of that report assessed the sensitivity of the SE as 61.49% and specificity as 74%. They compared it with the TRUS and respectively examination sensitivity was 76.35 and specificity 43.59%. They observed that the combination of both diagnostic methods (TRUS + SE) raised the effectiveness of the diagnostic methods of prostate gland: sensitivity – 79.9%, specificity – 86.7%.

Walz et al. [37] noticed that using elastography as the only method gave the sensitivity of 58.8% and specificity of 43.3%. In the biopsy of prostate gland those values were 67.8% sensitivity and 43.3% specificity. The combination of both methods showed a substantial rise of sensitivity up to 84.9%. Many more scientists, i.e. Salomon G and Brock [39, 40] accept elastography as a perfect completion of diagnostic methods which raise the sensitivity and specificity of the examination as well the biopsy precision. Salomon [40] assesses method sensitivity to 75.4% and method specificity to 76.6%. Tsutsumi et al. [41] observed that the effectiveness of the method does not depend on tumor localization. They examined 51 patients and elastography was made before the histopathology. In the examined group in 15 (29%) patients elastography was 100% effective. In 28 patients (55%) the localization of the tumor was correct but some inaccuracies appeared. In 8 (16%) patients elastography did not show correct focus and did not detect the tumor. Those findings made them divide the prostate gland into three parts: anterior, middle and posterior. In 30 (94%) out of 32 patients elastography detected the tumor in anterior region correctly and in 13 (76%) out of 17 patients in middle part. The assessment of the tumor in posterior area was the most difficult – 16/28 (57%). Elastography is a good complementary of other diagnostic methods. This method still needs research and training for people who perform it.

Conclusions

Sonoelastography is a novel technique of imaging, which enables the representation of tissues and organs with the evaluation of their elasticity. Ultrasound devices equipped with sonoelastography option enable more accurate imaging and evaluation of the nature of lesions situated at small depth, e.g. breast, thyroid, testicles, prostate, some groups of lymph nodes. The method is applicable mainly in diagnosing malignant lesions and the evaluation of hepatic fibrosis. It increases the accuracy of ultrasound in diagnostics and in the evaluation of the stage of malignant lesions. It also helps to indicate more precisely the areas that require the biopsy.

References

- [1] Ophir J, Alam SK, Garra BS, Kallel F, Konofagou EE, Krouskop T, Merritt ChRB, Righetti R, Souchon R, Srinivasan S, Varghese T: Elastography: Imaging the elastic properties of soft tissue with ultrasound. *J Med Ultrasonics* 2002, 29 (Winter), 155–171.
- [2] Parker KJ, Taylor, LS, Gracewski, S, & Rubens, DJ: A unified view of imaging the elastic properties of tissue. *The Journal of the Acoustical Society of America* 2005, 117, 2705.

- [3] **Bamber J**: EFSUMB guidelines and recommendations on the clinical use of ultrasound elastography. Part 1: Basic principles and technology. *Ultraschall Med* 2013 Apr, 34, 169–184.
- [4] **Cosgrove D**: EFSUMB guidelines and recommendations on the clinical use of ultrasound elastography. Part 2: Clinical applications. *Ultraschall Med* 2013, 34, 238–253.
- [5] **Itoh A, Ueno E, Tohno E, Kamma H, Takahashi H, Shiina T, Yamakawa M, Matsumura T**: Clinical application of US elastography for diagnosis. *Radiology* 2006, 239, 341–350.
- [6] **Vorländer Ch, Wolff J, Saalabian S, Lienenlücke RH, Wahl RA**: Real-time ultrasound elastography – a noninvasive diagnostic procedure for evaluating dominant thyroid nodules. *Langenbecks Arch Surg* 2010, 395, 865–871.
- [7] **Sarvazyan A, Hall TJ, Urban MW, Fatemi M, Aglyamov SR, Garra BS**: An overview of elastography – an emerging branch of medical imaging. *Curr Med Imaging Rev* 2011, 7, 255–282.
- [8] **Lerner RM, Parker KJ, Holen J, Gramiak R, Waag RC**: Sono-elasticity: Medical elasticity images derived from ultrasound signals in mechanically vibrated targets. In *Acoustical imaging*. Springer US 1989, 317–327.
- [9] **Aguilo MA, Aquino W, Brigham JC, Fatemi M**: An inverse problem approach for elasticity imaging through vibroacoustics. *IEEE Trans Med Imaging* 2010, 29, 1012–1021.
- [10] **Sandrin L, Fourquet B, Hasquenoph JM, Yon S, Fournier C, Mal F, Christidis C, Ziol M, Poulet B, Kazemi F, Beaugrand M, Palau R**: Transient elastography: a new noninvasive method for assessment of hepatic fibrosis. *Ultrasound Med Biol* 2003, 29, 1705–1713.
- [11] **Das D, Gupta M, Kaur H, Kalucha A**: Elastography: the next step. *J Oral Sci*. 2011 Jun, 53, 137–141.
- [12] **Xu W, Shi J, Zeng X, Li X, Xie WF, Guo J, Lin Y**: EUS elastography for the differentiation of benign and malignant lymph nodes: a meta-analysis. *Gastrointest Endosc* 2011, 74, 1001–1009.
- [13] **Giovannini M, Thomas B, Erwan B, Christian P, Fabrice C, Benjamin E, Genevieve M, Paolo A, Pierre D, Robert Y, Walter S, Hanz S, Carl S, Christoph D, Pierre E, Jean-Luc VL, Jacques D, Peter V, Andrian S**: Endoscopic ultrasound elastography for evaluation of lymph nodes and pancreatic masses: A multicenter study. *World J Gastroenterol* 2009, 7, 15, 1587–1593.
- [14] **Schaar JA, de Korte CL, Mastik F, Strijder C, Pasterkamp G, Boersma E, Serruys PW, van der Steen AFW**: Characterizing vulnerable plaque features with intravascular elastography. *Circulation* 2003, 25, 108, 2636–2641.
- [15] **Friedrich-Rust M, Ong M-F, Martens S, Sarrazin C, Bojunga J, Zeuzem S, Herrmann E**: Performance of transient elastography for the staging of liver fibrosis: a meta-analysis. *Gastroenterology* 2008, 134, 960–974.
- [16] **Kirk GD, Astemborski J, Mehta SH, Spoler C, Fisher C, Allen D, Higgins Y, Moore RD, Afdhal N, Torbenson M, Sulkowski M, Thomas DL**: Assessment of Liver Fibrosis by Transient Elastography in Persons with Hepatitis C Virus Infection or HIV–Hepatitis C Virus Coinfection. *Clin Inf Dis* 2009, 48, 963–972.
- [17] **Cho SH, Lee JY, Han JK, Choi BI**: Acoustic radiation force impulse elastography for the evaluation of focal solid hepatic lesions: preliminary findings. *Ultrasound Med Biol* 2010, 36, 202–208.
- [18] **Friedman SL**: Evolving challenges in hepatic fibrosis. *Nature reviews Gastroenterol Hepatol* 2010, 7, 8, 425.
- [19] **Lai C, Yuen M, Fung JY**: Clinical Application of Transient Elastography (Fibroscan) in Liver Diseases. *Medical Bulletin* 2009, 14, 22–25.
- [20] **Castéra L, Vergniol J, Foucher J, Le Bail B, Chanteloup E, Haaser M, de Lédinghen V**: Prospective comparison of transient elastography, Fibrotest, APRI, and liver biopsy for the assessment of fibrosis in chronic hepatitis C. *Gastroenterology* 2005, 128, 343–350.
- [21] **Cobbold JFL, Morin S, Taylor-Robinson SD**: Transient elastography for the assessment of chronic liver disease: Ready for the clinic? *World J Gastroenterol* 2007, 13, 36, 4791.
- [22] **Ferraioli G, Tinelli C, Dal Bello B, Zicchetti M, Filice G, Filice C**: Accuracy of real-time shear wave elastography for assessing liver fibrosis in chronic hepatitis C: A pilot study. *Hepatology* 2012, 56, 2125–2133.
- [23] **Bavu É, Gennisson JL, Couade M, Bercoff J, Mallet V, Fink M, Pol S**: Noninvasive *In Vivo* Liver Fibrosis Evaluation Using Supersonic Shear Imaging: A Clinical Study on 113 Hepatitis C Virus Patients. *Ultrasound Med Biol* 2011, 37, 1361–1373.
- [24] **Chen S, Sanchez W, Callstrom MR, Gorman B, Lewis JT, Sanderson SO, Metz S**: Assessment of liver viscoelasticity by using shear waves induced by ultrasound radiation force. *Radiology* 2013, 266, 964–970.
- [25] **Garra, BS, Cespedes, EI, Ophir J, Spratt SR, Zurbier RA, Magnant CM, Pennanen MF**: Elastography of breast lesions: initial clinical results. *Radiology* 1997, 202, 79–86.
- [26] **Itoh A, Ueno E, Tohno E, Kamma H, Takahashi H, Shiina T, Matsumura T**: Breast Disease: Clinical Application of US Elastography for Diagnosis. *Radiology* 2006, 239, 341–350.
- [27] **Hui H Zhi, Bing B Ou, Bao-Ming BM Luo, Xia X Feng, Yan-Ling YL Wen, Hai-Yun HY Yang**: Comparison of Ultrasound Elastography, Mammography, and Sonography in the Diagnosis of Solid Breast Lesions. *J Ultrasound Med* 2007, 26, 807–815.
- [28] **Bojunga J, Herrmann E, Meyer G, Weber S, Zeuzem S, Friedrich-Rust M**: Real-time elastography for the differentiation of benign and malignant thyroid nodules: a meta-analysis. *Thyroid* 2010 Oct, 20, 1145–1150.
- [29] **Bhatia KS, Tong CS, Cho CC, Yuen EH, Lee YY, Ahuja AT**: Shear wave elastography of thyroid nodules in routine clinical practice: preliminary observations and utility for detecting malignancy. *Eur Radiol* 2012 Nov, 22, 2397–2406.
- [30] **Sebag F, Vaillant-Lombard J, Berbis J, Griset V, Henry JF, Petit P, Oliver C**: Shear wave elastography: a new ultrasound imaging mode for the differential diagnosis of benign and malignant thyroid nodules. *J Clin Endocrinol Metab* 2010 Dec, 95, 5281–5288.
- [31] **Sporea I, Sirlu R, Bota S, Vlad M, Popescu A, Zosin I**: ARFI elastography for the evaluation of diffuse thyroid gland pathology: Preliminary results. *World J Radiol* 2012 Apr 28, 4, 174–178.

- [32] **Wojcinski S, Dupont J, Schmidt W, Cassel M, Hillemanns P:** Real-time ultrasound elastography in 180 axillary lymph nodes: elasticity distribution in healthy lymph nodes and prediction of breast cancer metastases. *BMC Med Imaging* 2012 Dec 19, 12, 35.
- [33] **Janssen J, Dietrich CF, Will U, Greiner L:** Endosonographic elastography in the diagnosis of mediastinal lymph nodes. *Endoscopy* 2007, 39, 952–957.
- [34] **Choi JJ, Kang BJ, Kim SH, Lee JH, Jeong SH, Yim HW, Song BJ, Jung SS:** Role of sonographic elastography in the differential diagnosis of axillary lymph nodes in breast cancer. *J Ultrasound Med* 2011 Apr, 30, 429–436.
- [35] **Lyshchik A, Higashi T, Asato R, Tanaka S, Ito J, Hiraoka M, Insana MF, Brill AB, Saga T, Togashi K:** Cervical lymph node metastases: diagnosis at sonoelastography – Initial experience. *Radiology* 2007, 243, 258–267.
- [36] **Pozzi E, Mantica G, Gastaldi C, Berardinelli M, Choussos D, Bianchi CM, Roggia A:** The role of the elastography in the diagnosis of prostate cancer: a retrospective study on 460 patients. *Arch Ital Urol Androl* 2012 Sep, 84, 151–154.
- [37] **Walz J, Marcy M, Pianna JT, Brunelle S, Gravis G, Salem N, Bladou F:** Identification of the prostate cancer index lesion by real-time elastography: considerations for focal therapy of prostate cancer. *World J Urol* 2011 Oct, 29, 589–594.
- [38] **Brock M, Eggert T, Löppenber B, Braun K, Roghmann F, Palisaar RJ, Noldus J, von Bodman C:** Value of Real-Time Elastography to Guide the Systematic Prostate Biopsy in Men with Normal Digital Rectal Exam. *Aktuelle Urol* 2013 Jan, 44, 40–44.
- [39] **Salomon G, Köllerman J, Thederan I, Chun FK, Budäus L, Schlomm T, Isbarn H, Heinzer H, Huland H, Graefen M:** Evaluation of prostate cancer detection with ultrasound real-time elastography: a comparison with step section pathological analysis after radical prostatectomy. *Eur Urol* 2008 Dec 54, 1354–1362.
- [40] **Tsutsumi M, Miyagawa T, Matsumura T, Kawazoe N, Ishikawa S, Shimokama T, Shiina T, Miyanaga N, Akaza H:** The impact of real-time tissue elasticity imaging (elastography) on the detection of prostate cancer: clinico-pathological analysis. *Int J Clin Oncol* 2007 Aug, 12, 250–255.

Address for correspondence:

Krzysztof Kaczorowski
Department of Radiology
Wroclaw Medical University
M. Curie-Skłodowskiej 68
50-369 Wrocław
Poland
E-mail: kkaczorowski.umedw@gmail.com

Conflict of interest: None declared

Received: 06.05.2014

Revised: 25.06.2014

Accepted: 01.07.2014