

US Artifacts¹

CME FEATURE

See accompanying test at http://www.rsna.org/education/lrg_cme.html

LEARNING OBJECTIVES FOR TEST 6

After reading this article and taking the test, the reader will be able to:

- List the assumptions of US image processing.
- Describe the imaging features of US artifacts.
- Discuss the physical origins of US artifacts.

TEACHING POINTS

See last page

Myra K. Feldman, MD • Sanjeev Katyal, MD • Margaret S. Blackwood, MS

Image artifacts are commonly encountered in clinical ultrasonography (US) and may be a source of confusion for the interpreting physician. Some artifacts may be avoidable and arise secondary to improper scanning technique. Other artifacts are generated by the physical limitations of the modality. US artifacts can be understood with a basic appreciation of the physical properties of the ultrasound beam, the propagation of sound in matter, and the assumptions of image processing. US artifacts arise secondary to errors inherent to the ultrasound beam characteristics, the presence of multiple echo paths, velocity errors, and attenuation errors. The beam width, side lobe, reverberation, comet tail, ring-down, mirror image, speed displacement, refraction, attenuation, shadowing, and increased through-transmission artifacts are encountered routinely in clinical practice. Recognition of these artifacts is important because they may be clues to tissue composition and aid in diagnosis. The ability to recognize and remedy potentially correctable US artifacts is important for image quality improvement and optimal patient care.

©RSNA, 2009 • radiographics.rsna.org

Introduction

In radiologic imaging, the term *artifact* is used to describe any part of an image that does not accurately represent the anatomic structures present within the subject being evaluated. In ultrasonography (US), artifacts may cause structures to appear in an image that are not present anatomically or a structure that is present anatomically may be missing from the image. US artifacts may also show structures as present but incorrect in location, size, or brightness (1). US is prone to numerous imaging artifacts, and these are commonly encountered in clinical practice. Artifacts have the potential to interfere with image interpretation. To avoid confusion, the radiologist should be able to recognize artifacts when they occur. Physicians who understand the physical explanation of these artifacts will be able to use this knowledge to improve both the image quality of their scans and the diagnostic power of their interpretations.

The creation of a US image is based on the physical properties of ultrasound pulse formation, the propagation of sound in matter, the interaction of sound with reflective interfaces, and echo detection and processing. **Ultrasound display equipment relies on physical assumptions to assign the location and intensity of each received echo.** These assumptions are that the echoes detected originated from within the main ultrasound beam, an echo returns to the transducer after a single reflection, the depth of an object is directly related to the amount of time for an ultrasound pulse to return to the transducer as an echo, the speed of sound in human tissue is constant, the sound beam and its echo travel in a straight path, and the acoustic energy in an ultrasound field is uniformly attenuated.

In clinical sonography, these assumptions are often not maintained; when this occurs, echoes may be displayed erroneously and perceived as artifact. Artifacts thus arise secondary to errors inherent to the ultrasound beam characteristics, the presence of multiple echo paths, velocity errors, and attenuation errors (2). In this article, these errors and the types of artifacts they create are discussed. For each artifact, emphasis is placed on the physical explanation, imaging appearance, diagnostic importance, and when applicable, scanning technique modifications that can be applied to improve image quality.

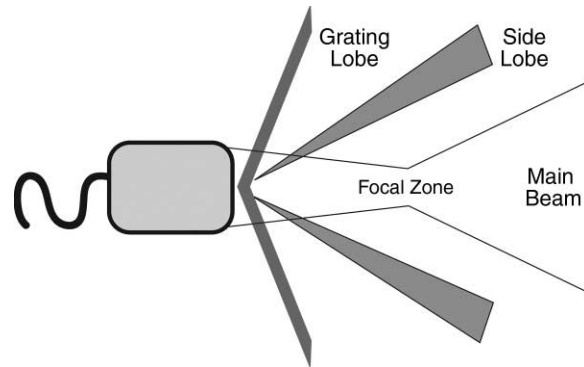


Figure 1. Diagram of an ultrasound beam. The main ultrasound beam narrows as it approaches the focal zone and then diverges. Grating lobes and side lobes are forms of off-axis energy.

Artifacts Associated with Ultrasound Beam Characteristics

US image processing assumes that the echoes detected originated from within the main ultrasound beam. The ultrasound beam exits the transducer as a complex three-dimensional bow-tie shape with additional off-axis low-energy beams, which are referred to as side lobes and grating lobes (3,4) (Fig 1). **A strong reflector located outside of the main ultrasound beam may generate echoes that are detectable by the transducer.** These echoes will be falsely displayed as having originated from within the main beam. This form of artifact is more likely to be recognized when the misplaced echoes overlap an expected anechoic structure (2).

Beam width artifact can be identified by understanding the shape of the ultrasound beam. The main ultrasound beam exits the transducer at approximately the same width as the transducer, then narrows as it approaches the focal zone and widens again distal to the focal zone (3). The distal beam may widen beyond the actual width of the transducer. A highly reflective object located within the widened beam beyond the margin of the transducer may generate detectable echoes. The ultrasound display assumes that these echoes originated from within the narrow imaging plane and displays them as such (Fig 2a, 2b). Clinically, beam width artifact may be recognized when a structure that should be anechoic such as the bladder contains peripheral echoes. If this artifact is recognized during scanning, image quality may be improved by adjusting the focal zone to the level of interest and by

Teaching Point

Teaching Point

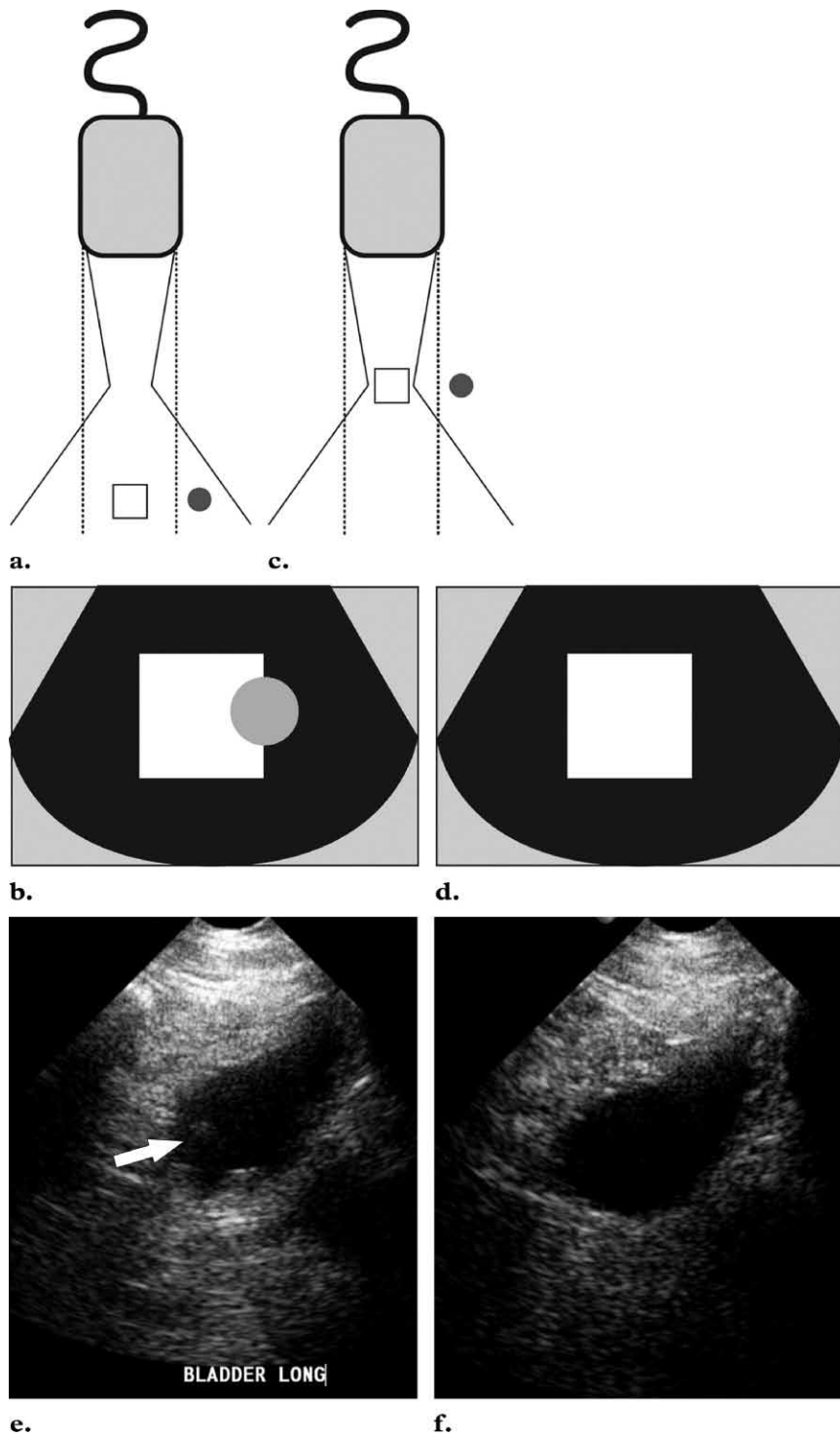


Figure 2. Beam width artifact. **(a)** The ultrasound image localization software assumes an imaging plane as indicated by the dotted lines. **(b)** Echoes generated by the object located in the peripheral field (gray circle) are displayed as overlapping the object of interest (white square). **(c, d)** Adjusting the focal zone and placing the object of interest within the center of the focal zone **(c)** will eliminate the misplaced echoes on the display **(d)**. **(e)** Longitudinal US image of a partially filled bladder shows echoes (arrow) in the expected anechoic urine. The focal zone is improperly set too shallow. **(f)** Longitudinal US image obtained after adjustment of the focal zone and optimal placement of the transducer shows resolution of the intravesical echoes.

placing the transducer at the center of the object of interest (Fig 2c–2f) (5).

Side lobes are multiple beams of low-amplitude ultrasound energy that project radially from

the main beam axis (Fig 1). Side lobe energy is generated from the radial expansion of piezoelectric crystals and is seen primarily in linear-array

transducers (3,6). Strong reflectors present in the path of these low-energy, off-axis beams may create echoes detectable by the transducer. These echoes will be displayed as having originated from within the main beam in the side lobe artifact (Fig 3). As with beam width artifact, this phenomenon is most likely to be recognized as extraneous echoes present within an expected anechoic structure such as the bladder.

Artifacts Associated with Multiple Echoes

US assumes that an echo returns to the transducer after a single reflection and that the depth of an object is related to the time for this round trip. **In the presence of two parallel highly reflective surfaces, the echoes generated from a primary ultrasound beam may be repeatedly reflected back and forth before returning to the transducer for detection (Fig 4a) (2,3). When this occurs, multiple echoes are recorded and displayed.** The echo that returns to the transducer after a single reflection will be displayed in the proper location. The sequential echoes will take longer to return to the transducer, and the ultrasound processor will erroneously place the delayed echoes at an increased distance from the transducer. At imaging, this is seen as multiple equidistantly spaced linear reflections and is referred to as reverberation artifact (Fig 4b, 4c).

Comet tail artifact is a form of reverberation. In this artifact, the two reflective interfaces and thus sequential echoes are closely spaced. On the display, the sequential echoes may be so close together that individual signals are not perceivable. In addition, the later echoes may have decreased amplitude secondary to attenuation; this decreased amplitude is displayed as decreased width (1,2). The result is an artifact caused by the principle of reverberation but with a triangular, tapered shape (Fig 4d).

In the past, ring-down artifact has been thought to be a variant of comet tail artifact.

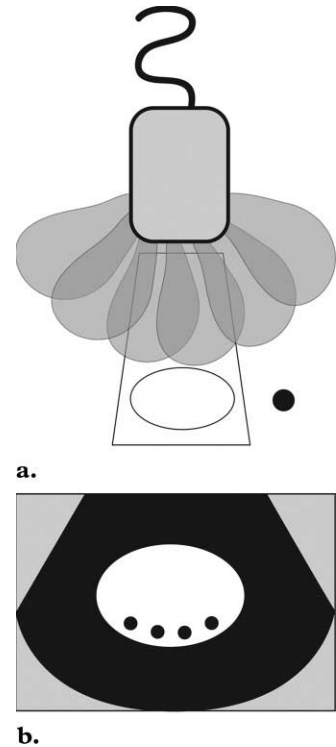


Figure 3. Side lobe artifact. **(a)** Diagram shows multiple beams of off-axis side lobe ultrasound energy encountering an object (black circle). **(b)** The display assumes that the echoes returning from this off-axis object came from the main beam and misplaces and duplicates the structure.

This assumption was based on the often similar appearance of the two artifacts. Figure 5a–5c illustrates the theory that in ring-down artifact, the transmitted ultrasound energy causes resonant vibrations within fluid trapped between a tetrahedron of air bubbles. These vibrations create a continuous sound wave that is transmitted back to the transducer (Fig 5d). This phenomenon is displayed as a line or series of parallel bands extending posterior to a gas collection. Despite the similar sonographic appearance, these two artifacts have separate mechanisms (7).

Mirror image artifacts are also generated by the false assumption that an echo returns to the transducer after a single reflection. In this scenario, the primary beam encounters a highly reflective interface. The reflected echoes then encounter the “back side” of a structure and are reflected back toward the reflective interface before being reflected to the transducer for

Teaching
Point

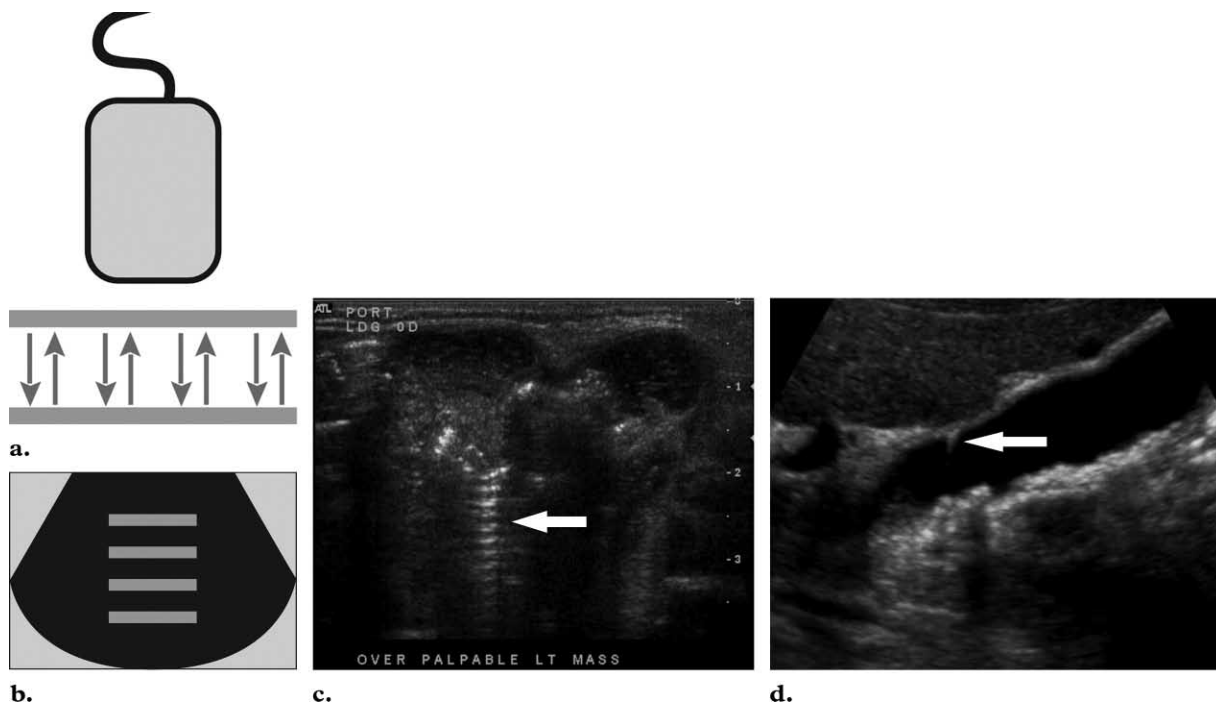


Figure 4. Reverberation artifact. **(a)** Diagram shows ultrasound echoes being repeatedly reflected between two highly reflective interfaces. **(b)** The display shows multiple equally spaced signals extending into the deep field. **(c)** Transverse US image obtained over a palpable mass in a neonate shows reverberation artifact (arrow). **(d)** Longitudinal US image of the gallbladder shows comet tail artifact (arrow) caused by cholesterol crystals in Rokitansky-Aschoff sinuses. This finding is diagnostic of adenomyomatosis. Shadowing gallstones are also identified.

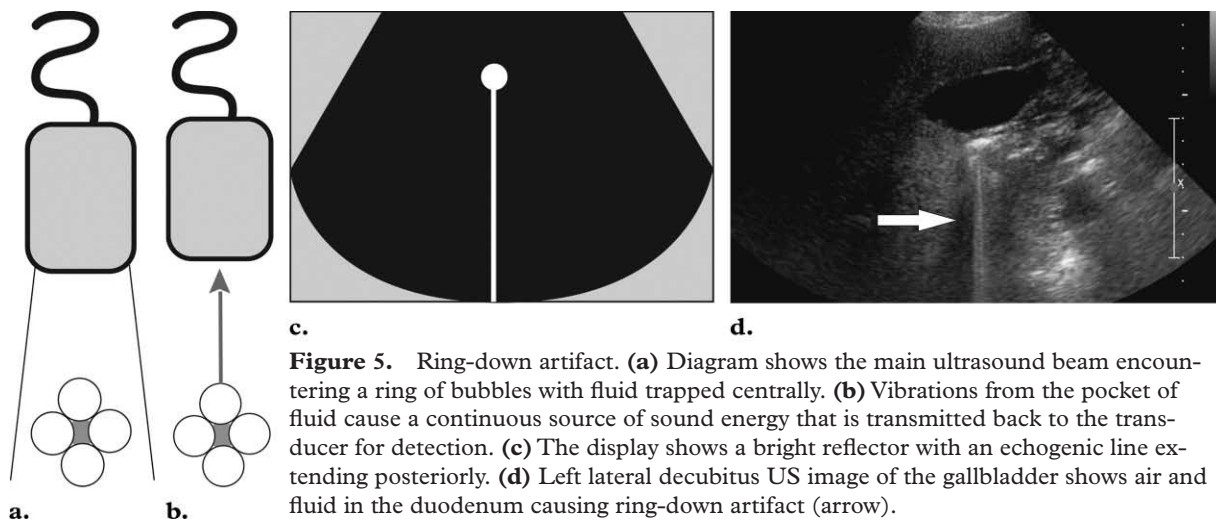
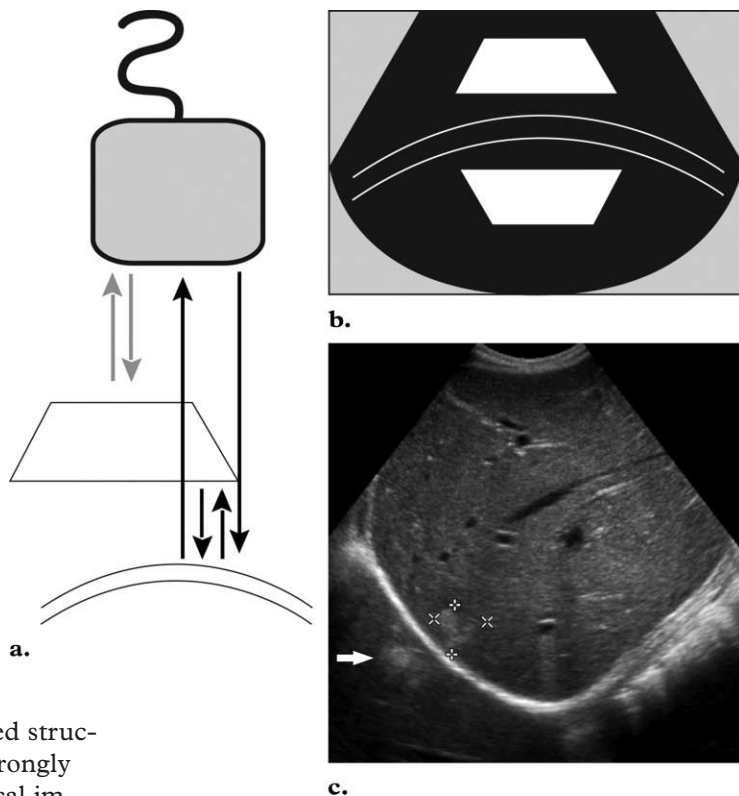


Figure 5. Ring-down artifact. **(a)** Diagram shows the main ultrasound beam encountering a ring of bubbles with fluid trapped centrally. **(b)** Vibrations from the pocket of fluid cause a continuous source of sound energy that is transmitted back to the transducer for detection. **(c)** The display shows a bright reflector with an echogenic line extending posteriorly. **(d)** Left lateral decubitus US image of the gallbladder shows air and fluid in the duodenum causing ring-down artifact (arrow).

Figure 6. Mirror image artifact. (a) In this diagram, the gray arrows represent the expected reflective path of the ultrasound beam. These echoes are displayed properly. The black arrows show an alternative path of the primary ultrasound beam. In this path, the primary ultrasound beam encounters the deeper reflective interface first. (b) The echoes from the deeper reflective interface take longer to return to the transducer and are misplaced on the display. (c) Longitudinal US image obtained at the level of the right hepatic lobe shows an echogenic lesion in the right hepatic lobe (cursors) and a duplicated echogenic lesion (arrow) equidistant from the diaphragm overlying the expected location of lung parenchyma.



detection. The display shows a duplicated structure equidistant from but deep to the strongly reflective interface (Fig 6a, 6b). In clinical imaging, this duplicated structure is commonly identified at the level of the diaphragm, with the pleural-air interface acting as the strong reflector. At this location, the artifact is easily recognized as hepatic parenchyma present in the expected location of lung (Fig 6c).

Artifacts Associated with Velocity Errors

The speed of sound within a material is dependent on its density and elastic properties. US image processing assumes a constant speed of sound in human tissue of 1540 m/sec. In clinical sonography, the ultrasound beam may encounter a variety of materials such as air, fluid, fat, soft tissue, and bone. The velocity of sound in these materials is listed in Table 1 (3).

Table 1
Density and Speed of Ultrasound for Selected Tissues

Material	Density (kg/m ³)	C (m/sec)
Air	1.2	330
Fat	924	1450
Soft tissue	1050	1540
Bone	1912	4080

Source.—Reference 3.

When sound travels through material with a velocity significantly slower than the assumed 1540 m/sec, the returning echo will take longer to return to the transducer. The image processor assumes that the length of time for a single round trip of an echo is related only to the distance traveled by the echo. The echoes are thus displayed deeper on the image than they really are (Fig 7a, 7b). This is referred to as the speed displacement artifact; in clinical imaging, it is often recognized

Teaching
Point

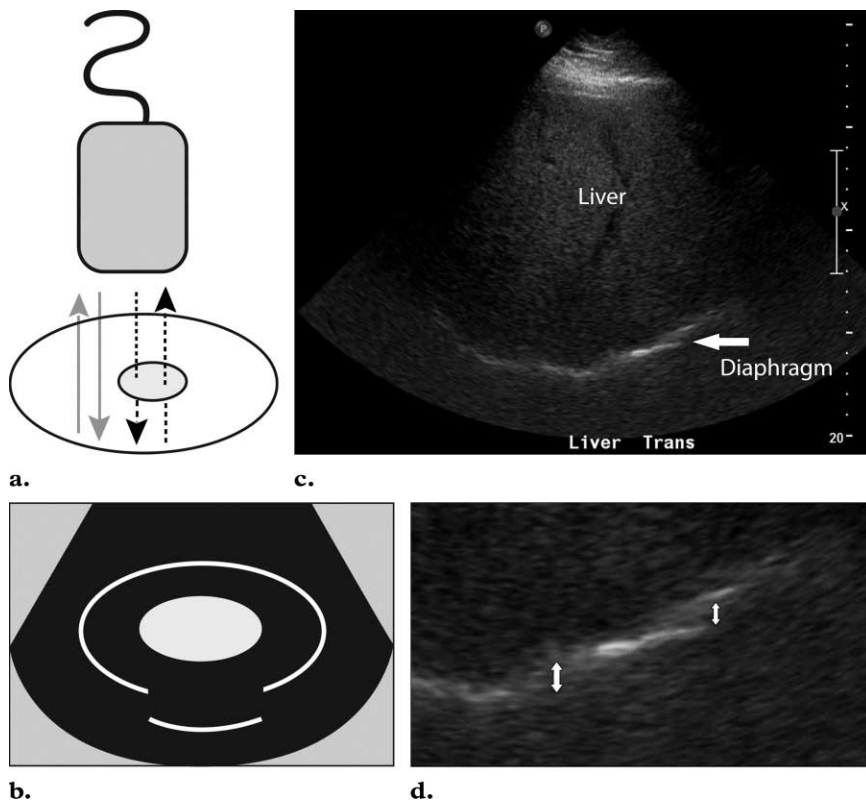


Figure 7. Speed displacement artifact. **(a)** In this diagram, the gray arrows represent the expected reflected path of the ultrasound beam. The echoes returning from the posterior wall of the depicted structure will be displayed properly. The black arrows represent the path of an ultrasound beam that encounters an area of focal fat. The dashed lines indicate that the sound beam travels slower in the focal fat than in the surrounding tissue. **(b)** Because the round trip of this echo is longer than expected, the posterior wall is displaced deeper on the display. **(c, d)** Transverse US image of the liver **(c)** and close-up detail image **(d)** show that the interface between the liver and the diaphragm (arrow in **c**) is discontinuous and focally displaced (arrows in **d**). This appearance may be explained by areas of focal fat within the liver.

when the ultrasound beam encounters an area of focal fat (Fig 7c, 7d).

A change in velocity of the ultrasound beam as it travels through two adjacent tissues with different density and elastic properties may produce a refraction artifact. In refraction, nonperpendicular incident ultrasound energy encounters an interface between two materials with different speeds of sound. When this occurs, the incident ultrasound beam changes direction. The degree

of this change in direction is dependent on both the angle of the incident ultrasound beam and the difference in velocity between the two media. This relationship is described by Snell's law:

$$\sin\theta_r / \sin\theta_i = c_2 / c_1,$$

where c = velocity, i = incidence, and r = refraction. The ultrasound display assumes that the

beam travels in a straight line and thus misplaces the returning echoes to the side of their true location (Fig 8). In clinical imaging, this artifact may be recognized in pelvic structures deep to the junction of the rectus muscles and midline fat. Refraction artifact may cause structures to appear wider than they actually are or may cause an apparent duplication of structures (2).

Artifacts Associated with Attenuation Errors

As an ultrasound beam travels through the body, its energy becomes attenuated secondary to absorption and scatter (3). An echo that travels a greater distance in the body will be attenuated more than an echo of similar energy that travels a shorter path. Ultrasound processing incorporates “compensation amplification” of echoes that take longer to return to the transducer. In this process, the echoes that return later are amplified more than earlier returning echoes. This serves to make the image appear more uniform in the deep field. “Time gain compensation” refers to a user-adjustable form of compensation (1,3). The attenuation coefficient expresses the loss of ultrasound intensity per distance traveled and varies in different mediums (Table 2) (3).

When the ultrasound beam encounters a focal material that attenuates the sound to a greater or lesser extent than in the surrounding tissue, the strength of the beam distal to this structure will be either weaker or stronger than in the surrounding field. Thus, when the ultrasound beam encounters a strongly attenuating or highly reflective structure, the amplitude of the beam distal to this structure is diminished (Fig 9a). The echoes returning from structures beyond the highly attenuating structure will also be diminished. In clinical imaging, this phenomenon is recognized as a dark or hypoechoic band

Teaching Point

Figure 8. Refraction artifact. (a) Diagram shows the refraction or change in direction of the obliquely angled incident ultrasound beam as it travels between two adjacent tissues with different sound propagation velocities ($C1$ and $C2$). The incident ultrasound beam with refraction encounters two structures. (b) The object in the path of the refracted portion of the beam is misplaced because the processor assumes a straight path of the beam.

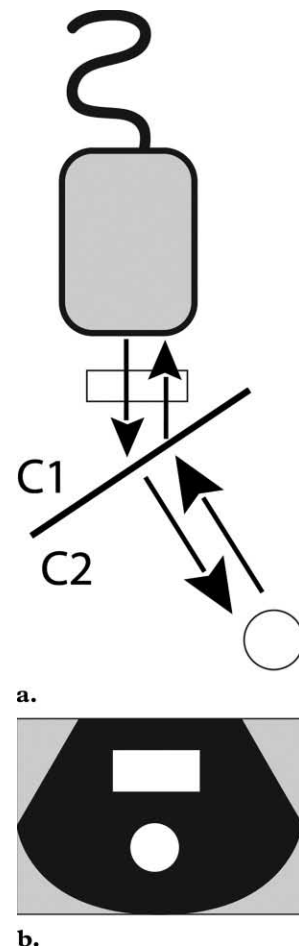


Table 2
Attenuation Coefficients for Selected Tissues at 1 MHz

Material	Attenuation Coefficient (dB/cm)
Water	0.0002
Soft tissue	0.3–0.8
Fat	0.5–1.8
Bone	13–26
Air	40

Source.—Reference 3.

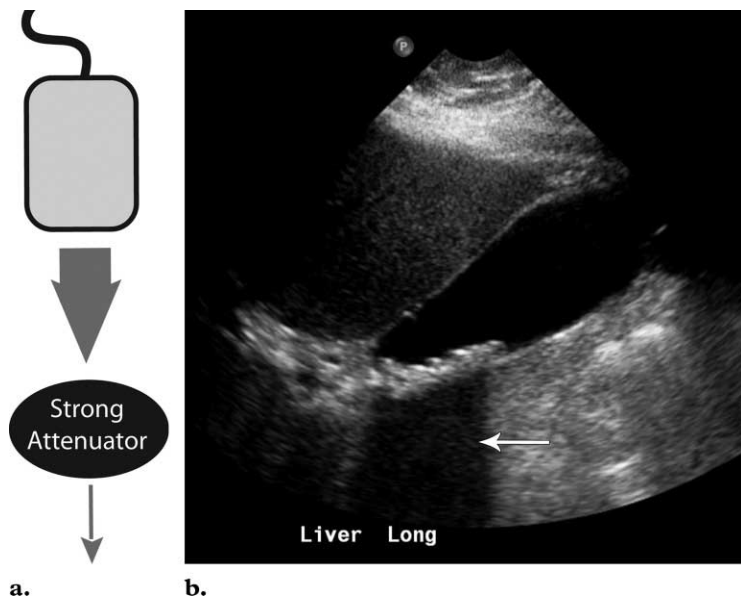


Figure 9. Shadowing. (a) Diagram shows the ultrasound beam encountering a strongly attenuating material. The echoes received from points distal to this material are significantly lower in intensity than echoes received from a similar depth. (b) Longitudinal US image of the gallbladder shows shadowing (arrow) posterior to echogenic gallstones.

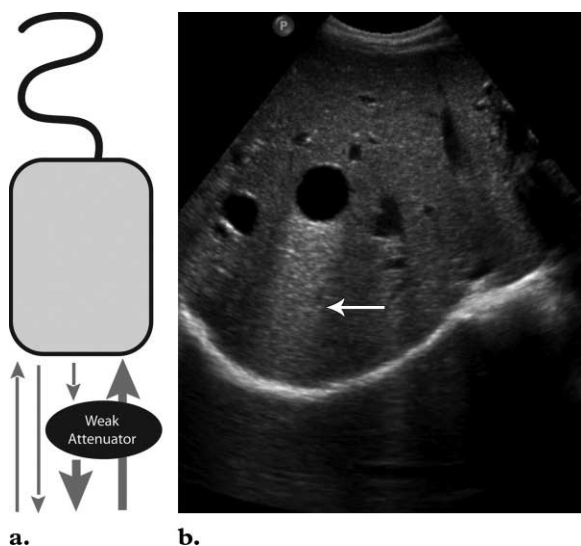
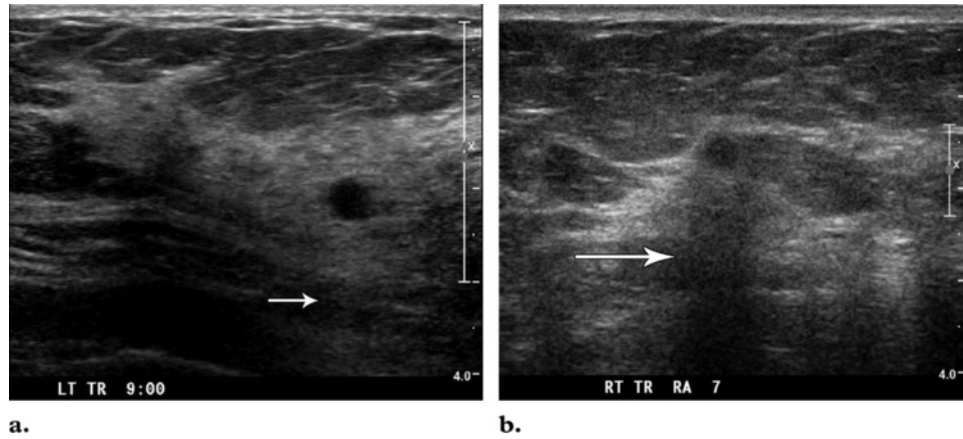


Figure 10. Increased through transmission. (a) Diagram shows the ultrasound beam encountering a focal weakly attenuating material. The echoes received from points distal to this material are higher in intensity than echoes received from a similar depth in the imaging plane. (b) Transverse US image of the liver shows hypoechoic and weakly attenuating hepatic cysts. The hepatic parenchyma distal to the cysts is falsely displayed as increased in intensity (arrow) secondary to increased through-transmission artifact.

known as a “shadow” deep to a highly attenuating structure (Fig 9b).

Similarly, when the ultrasound beam encounters a focal weakly attenuating structure within the imaging field, the amplitude of the beam

beyond this structure is greater than the beam amplitude at the same depth in the rest of the field (Fig 10a). The echoes returning from structures deep to the focal weak attenuator will be of higher amplitude and will be falsely displayed as increased in echogenicity. On the display, we identify this “increased through transmission” as a bright band extending from an object of low attenuation (Fig 10b). With an understanding of the attenuation characteristics of materials



a. **b.**
Figure 11. Use of attenuation artifacts to analyze the composition of tissue. **(a)** Transverse US image of the breast shows a small hypoechoic nodule with increased through transmission (arrow). The nodule was stable over a 2-year period in a patient with multiple cystic breast lesions. **(b)** Transverse US image of the breast shows a small hypoechoic nodule with posterior shadowing (arrow). The lesion was a pathologically proved breast cancer.

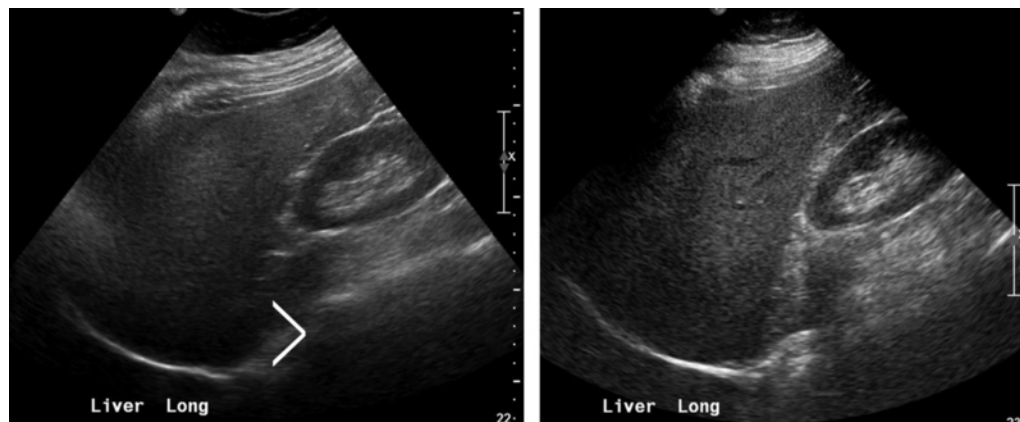
encountered in human anatomy, these “artifacts” can be used by the clinician to determine the composition of a structure on the basis of US appearance and can be used to narrow a differential diagnosis (Fig 11).

Attenuation is also dependent on the frequency of the ultrasound. Attenuation increases with increase in frequency. In soft tissues, the relationship between attenuation and frequency is linear. In bone and water, attenuation increases as the square of the frequency (3). In clinical imaging, the different tissues an ultrasound beam encounters attenuate the beam differently. If the attenuation coefficient for a material is great,

such as with fat, then the beam may not fully penetrate the imaging field. In this situation, deep structures may not be visualized. An appropriate-frequency transducer should be selected to optimize penetration (Fig 12).

Conclusions

Artifacts are commonplace in US. Often, these errors in image display are unavoidable and occur secondary to intrinsic physical properties of the ultrasound beam and its echo and to limitations of the display equipment. Recognition of these unavoidable artifacts is important because they may be clues to tissue composition and aid in diagnosis. The ability to recognize and remedy potentially correctable artifacts is important for image quality improvement and optimal patient care.



a. **b.**
Figure 12. Use of knowledge of ultrasound attenuation to improve image quality. **(a)** On a longitudinal US image of the liver obtained with a high-frequency transducer, the deep hepatic parenchyma is not well visualized (angle bracket). Disease in this portion of the liver may not be detected. **(b)** On a longitudinal US image of the liver obtained in the same patient with a lower-frequency transducer, the deep hepatic parenchyma is now well visualized.

Acknowledgments: The authors thank Amanda Achhammer, Amber Chaney, Beth Edson, Kelly Green-Elder, and Jennifer Quolke for their help in acquiring the US images and extend special thanks to Sean Biagi.

References

1. Kremkau FW. Diagnostic ultrasound principles and instruments. 5th ed. Philadelphia, Pa: Saunders, 1998; 147–157, 377–436.
2. Meire H, Cosgrove D, Dewbury K, Farrant P. Abdominal and general ultrasound. 2nd ed, vol 1. London, England: Churchill Livingstone, 2001; 47–65.
3. Bushberg JT, Seibert JA, Leidholdt EM, Boone JM. The essential physics of medical imaging. 2nd ed. Philadelphia, Pa: Lippincott Williams & Wilkins, 2002; 469–553.
4. Hangiandreou NJ. B-mode US: basic concepts and new technology. *RadioGraphics* 2003;23(4): 1019–1033.
5. Scanlan KA. Sonographic artifacts and their origins. *AJR Am J Roentgenol* 1991;156(6):1267–1272.
6. Laing FC, Kurtz AB. The importance of ultrasonic side-lobe artifacts. *Radiology* 1982;145(3):763–768.
7. Avruch L, Cooperberg PL. The ring-down artifact. *J Ultrasound Med* 1985;4(1):21–28.

US Artifacts

Myra K. Feldman, MD, et al

RadioGraphics 2009; 29:1179–1189 • Published online 10.1148/rg.294085199 • Content Codes: PH US

Page 1180

Ultrasound display equipment relies on physical assumptions to assign the location and intensity of each received echo.

Page 1180

A strong reflector located outside of the main ultrasound beam may generate echoes that are detectable by the transducer.

Page 1182

In the presence of two parallel highly reflective surfaces, the echoes generated from a primary ultrasound beam may be repeatedly reflected back and forth before returning to the transducer for detection (Fig 4a) (2,3). When this occurs, multiple echoes are recorded and displayed.

Page 1184

When sound travels through material with a velocity significantly slower than the assumed 1540 m/sec, the returning echo will take longer to return to the transducer. The image processor assumes that the length of time for a single round trip of an echo is related only to the distance traveled by the echo. The echoes are thus displayed deeper on the image than they really are (Fig 7a, 7b).

Page 1186

When the ultrasound beam encounters a focal material that attenuates the sound to a greater or lesser extent than in the surrounding tissue, the strength of the beam distal to this structure will be either weaker or stronger than in the surrounding field.