

## Pericapsular Nerve Group (PENG) Block for Hip Fracture

Laura Girón-Arango, MD,\*† Philip W.H. Peng, MBBS, FRCPC, Founder (Pain Med),\*†  
 Ki Jinn Chin, MBBS, MMed, FANZCA, FAMS, FRCPC,\*†  
 Richard Brull, MD, FRCPC,\* and Anahi Perlas, MD, FRCPC\*†

**Abstract:** Fascia iliaca block or femoral nerve block is used frequently in hip fracture patients because of their opioid-sparing effects and reduction in opioid-related adverse effects. A recent anatomical study on hip innervation led to the identification of relevant landmarks to target the hip articular branches of femoral nerve and accessory obturator nerve. Using this information, we developed a novel ultrasound-guided approach for blockade of these articular branches to the hip, the PENG (PEricapsular Nerve Group) block. In this report, we describe the technique and its application in 5 consecutive patients.

(Reg Anesth Pain Med 2018;43: 00–00)

Hip fracture is a common orthopedic emergency in the elderly, and it is associated with significant morbidity and mortality.<sup>1</sup> Surgical reduction and fixation are the definitive treatment in most patients.<sup>2</sup> Effective perioperative analgesia that minimizes the need for opioids and related adverse effects (such as delirium) is essential in this patient population.<sup>3,4</sup>

Regional analgesic techniques, including femoral nerve (FN) block, fascia iliaca block (FIB), and 3-in-1 FN block, are popular analgesic strategies, due mainly to their opioid-sparing effects and reduction in opioid-related adverse effects.<sup>5–7</sup> The effect size of analgesia from these blocks is only moderate,<sup>8</sup> and literature suggests that the obturator nerve (ON) is not covered.<sup>9,10</sup>

The anterior hip capsule is innervated by the ON, accessory obturator nerve (AON), and FN as reported by previous anatomic studies.<sup>11–13</sup> The anterior capsule is the most richly innervated section of the joint,<sup>14</sup> suggesting these nerves should be the main targets for hip analgesia. A recent anatomical study by Short et al<sup>15</sup> confirmed the innervation of the anterior hip by these 3 main nerves, but also found that the AON and FN play a greater role in the anterior hip innervation than previously reported.<sup>16</sup> This study also identified the relevant landmarks for those articular branches. The high articular branches from FN and AON are consistently found between the anterior inferior iliac spine (AIIS) and the iliopubic eminence (IPE), whereas the ON is located close to the inferomedial acetabulum. Using this information, we developed an ultrasound-guided technique for blockade of these articular branches to the hip, the PENG (PEricapsular Nerve Group) block. In this report, we describe the technique and its effective application in 5 patients with hip fracture.

## METHODS

Patients admitted to the Toronto Western Hospital with a fractured hip are assessed by the Acute Pain Service as part of a multidisciplinary care pathway. Patients with significant pain, opioid use, or opioid-related adverse effects are offered regional analgesia as a component of a multimodal analgesic regimen. We performed the PENG block in 5 patients following a discussion of the potential risks and benefits. Written informed consent was obtained from all 5 patients for this report.

Demographic information, types of hip fracture and subsequent surgery, and types of injectate in the regional block are noted in Table 1. Pain scores at rest and with a straight leg raise of the affected limb to 15 degrees were assessed before and 30 minutes after block performance. Before the procedure, all patients reported severe hip pain despite intravenous opioids (Fig. 1, A and B). In 4 of 5 cases, a single-injection block was performed in which 20 mL of 0.25% bupivacaine with epinephrine 1:400,000 was used. In the remaining case, 20 mL of 0.5% ropivacaine with epinephrine 1:200,000 plus dexamethasone 4 mg was used.

The regional block was performed with the patient in the supine position. A curvilinear low-frequency ultrasound probe (2–5 MHz) was initially placed in a transverse plane over the AIIS and then aligned with the pubic ramus by rotating the probe counterclockwise approximately 45 degrees (Figs. 2, 3). In this view, the IPE, the iliopsoas muscle and tendon, the femoral artery, and pectineus muscle were observed. A 22-gauge, 80-mm needle was inserted from lateral to medial in an in-plane approach to place the tip in the musculofascial plane between the psoas tendon anteriorly and the pubic ramus posteriorly. Following negative aspiration, the local anesthetic solution was injected in 5-mL increments while observing for adequate fluid spread in this plane for a total volume of 20 mL (Fig. 4).

## RESULTS

Thirty minutes after block placement, we evaluated all patients by asking them to flex at the hip and to perform a straight leg raise of the affected limb to 15 degrees. All patients were able to comply and reported significantly reduced pain scores compared with baseline (Fig. 1). In addition, no quadriceps weakness was clinically evident in any of the patients.

## DISCUSSION

Regional analgesia techniques are commonly used for pain management in patients with hip fractures as they provide reasonable analgesia with an opioid-sparing effect and are relatively safe.

A recent Cochrane review on nerve blocks for hip fractures, which included FIB, FN block, and 3-in-1 FN block, demonstrated high-quality evidence supporting a reduction in dynamic pain within 30 minutes of block placement. The effect size in this review was –3.4 points on a scale from 0 to 10.<sup>8</sup>

The cephalad spread of local anesthetic from both 3-in-1 and FIB has been examined with magnetic resonance imaging. The ON is consistently not covered. More importantly, the cephalad

From the \*Department of Anesthesia, Toronto Western Hospital; and †University Health Network, University of Toronto, Toronto, Ontario, Canada.

Accepted for publication April 14, 2018.

Address correspondence to: Philip W.H. Peng, MBBS, FRCPC, Founder (Pain Med), Department of Anesthesia, McL 2-405, TWH, 399 Bathurst Street, Toronto, Ontario, Canada M5T 2S8 (e-mail: philip.peng@uhn.ca).

A.P. has a research grant from Fisher and Pykel. P.W.H.P. has equipment support from Fujifilm/Sonosite Canada. The other authors declare no conflict of interest.

The authors have no sources of funding to declare for this article.

Copyright © 2018 by American Society of Regional Anesthesia and Pain Medicine

ISSN: 1098-7339

DOI: 10.1097/AAP.0000000000000847

TABLE 1. Characteristics of Patients

Cases	Sex	Age, y	ASA	Side	Hip Pathology	Type of Surgery	Type and Volume of Local Anesthetic
1	F	70	III	L	Intertrochanteric fracture	DHS fixation	Bupivacaine 0.25% with epinephrine 1:400,000 20 mL
2	F	80	III	L	Subcapital fracture	Hip hemiarthroplasty	Bupivacaine 0.25% with epinephrine 1:400,000 20 mL
3	M	68	IV	R	Metastatic tumor in femoral head and acetabulum	Total hip arthroplasty	Bupivacaine 0.25% with epinephrine 1:400,000 20 mL
4	M	62	II	L	Intertrochanteric fracture	DHS fixation	Bupivacaine 0.25% with epinephrine 1:400,000 20 mL
5	F	72	III	R	Subcapital fracture	Total hip arthroplasty	Ropivacaine 0.5% with epinephrine 1:200,000 20 mL and 4 mg of dexamethasone

ASA indicates American Society of Anesthesiologists; DHS, dynamic hip screw; F, female; L, left; M, male; R, right.

spread is unlikely to extend beyond the L5 level.<sup>9,10</sup> A recent anatomic study showed that the articular branches from the FN to the hip joint enter the iliacus muscle at the L4–L5 level and course deep to the psoas muscle and tendon between the AIIS and IPE before innervating the hip capsule (Fig. 5). The AON courses deep to the medial aspect of psoas muscle around the L5 level. It then

courses deep to the psoas around IPE to enter the anteromedial joint capsule (Fig. 5).<sup>17</sup> Therefore, neither the 3-in-1 nor the FIB is likely to consistently block the articular branches from the AON and FN.

In contrast, the targets of the regional block described in our case series were the articular branches of AON and FN between

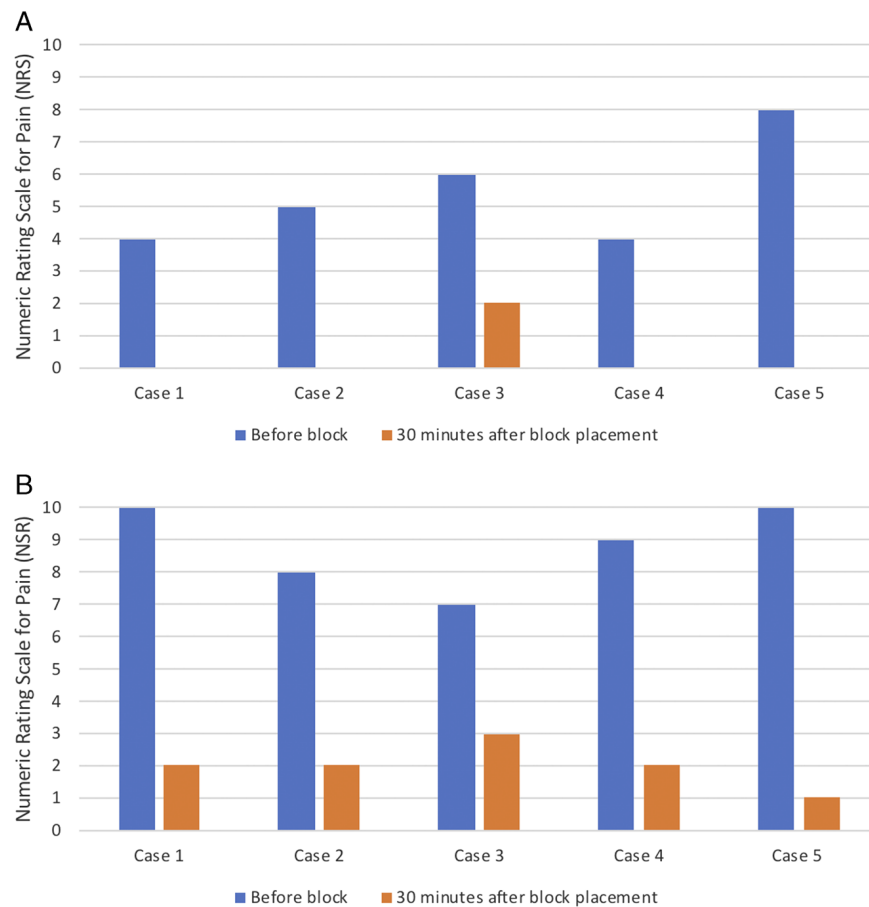
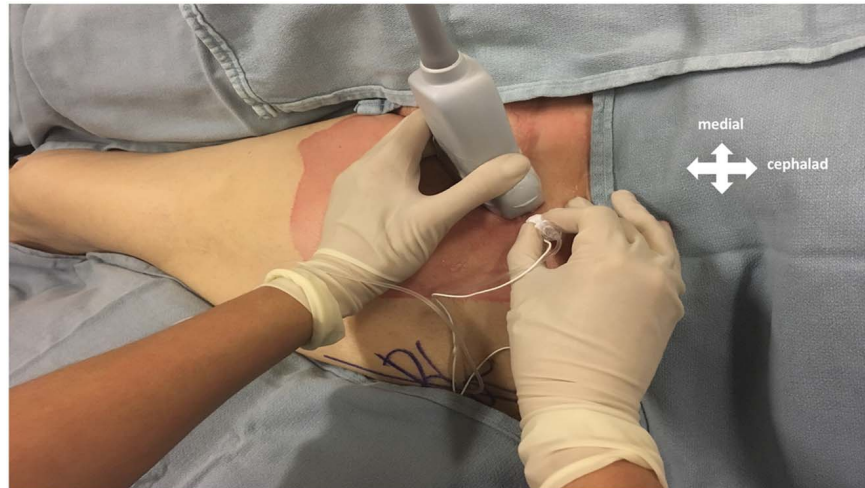
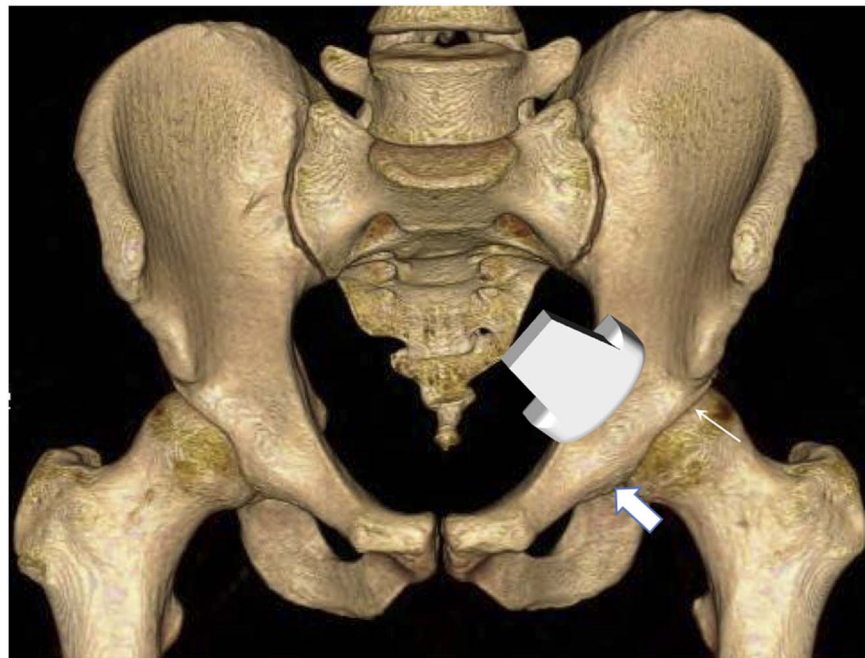


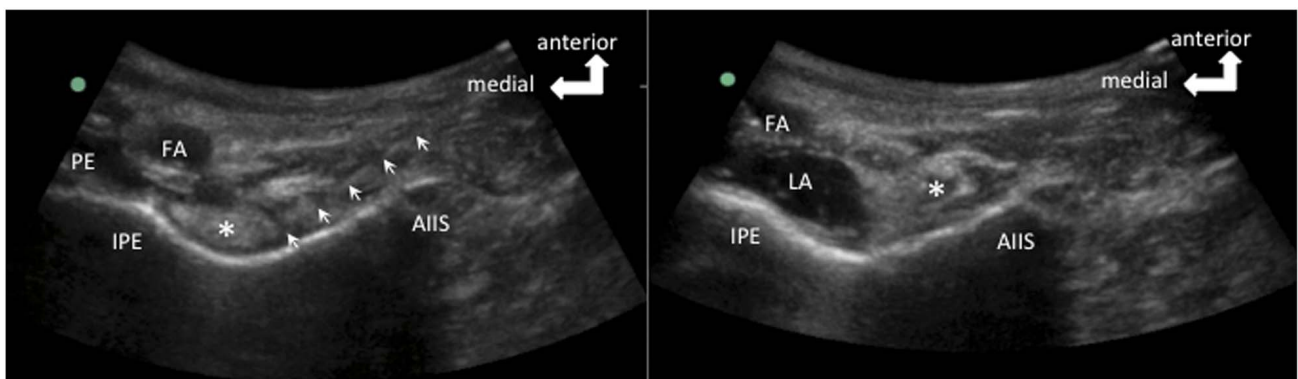
FIGURE 1. A, Rest pain score before and 30 minutes after the block. The postblock pain score for patients 1, 2, 4, and 5 were 0. Reproduced with permission from Philip Peng Educational Series. B, Dynamic pain score before and 30 minutes after the block. Reproduced with permission from Philip Peng Educational Series.



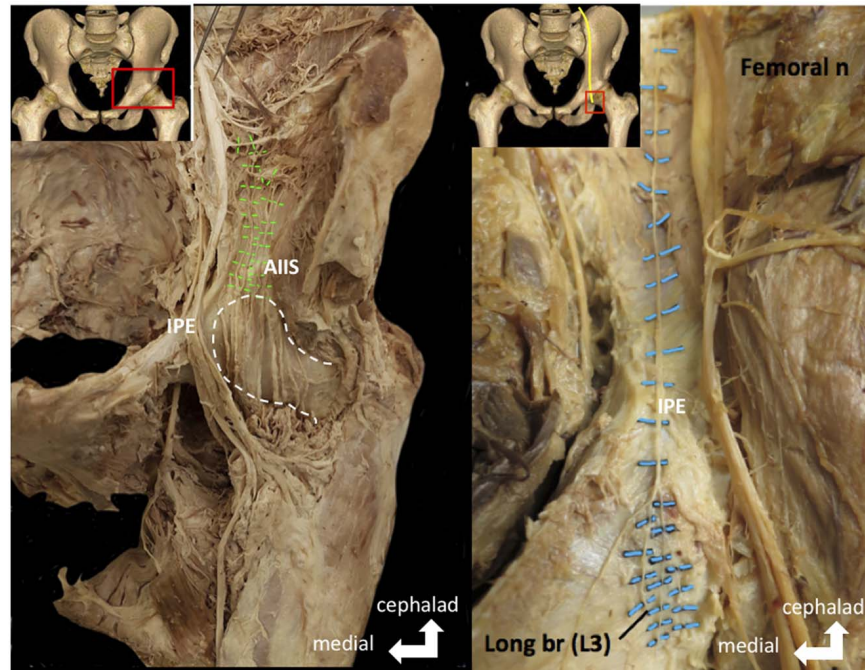
**FIGURE 2.** Figure showing the position of the hip, orientation of the ultrasound probe, and needle insertion. Reproduced with permission from Philip Peng Educational Series.



**FIGURE 3.** The area revealed by ultrasound in Fig. 2 is demonstrated in this figure. Line arrow: AIIS, block arrow: IPE. Reproduced with permission from Philip Peng Educational Series.



**FIGURE 4.** The corresponding sonogram from Fig. 3. The figure on the left shows the needle position. The needle is outlined by the arrows. The figure on the right shows the local anesthetic spread following injection. FA indicates femoral artery; LA, local anesthetic; PE, pectineus muscle. \*Psoas tendon. Reproduced with permission from Philip Peng Educational Series.



**FIGURE 5.** Anatomy of the articular branches of FN and accessory FNs in cadaveric dissection. The figure on the left side shows the articular branches of FN (highlighted in green) coursing between AIIS and IPE toward the hip capsule. The femoral head is outlined by the dotted line. The figure on the right side shows the course of the AON (highlighted in blue) passing over the IPE. The areas of dissection are shown in the insert on the left upper corners. Reproduced with permission from Philip Peng Educational Series.

AIIS and IPE. We are not able to comment on whether the local anesthetic would spread medially enough to reach the plane between the pectineus and obturator externus muscles (subpectineal plane [SPP]) where the articular branches of ON can be found. The SPP, which is identifiable by ultrasound, has been recently described by Nielsen et al.<sup>18</sup> as a target point for ON and its articular branches. Given the proximity of the SPP, it is conceivable that the local anesthetic injected in our cases may have spread to this plane. However, dye injection studies would be needed to confirm this possibility.

The median reduction of pain in our case series was 7 points, showing a larger decrease than the one previously reported for other regional techniques in hip fracture patients. Interestingly, the patients in our case report presented with different hip pathologies (intertrochanteric fracture, subcapital fracture, and femoral head metastases), and all 5 of them reported significant dynamic pain relief. In addition, given that our technique targets only the sensory branches, there is a potential motor-sparing effect compared with both the FIB and the FN block.

This is only a small case series, and there are limitations inherent to this type of publication, such as lack of ability to generalize, publication bias, danger of overinterpretation, and retrospective design.<sup>19</sup> However, there are merits of this type of publication such as the detection of novelties and generation of hypotheses. Although the FIB and FN have been shown to be effective in providing analgesia, there is room to improve the effect size of analgesia as discussed before. This consecutive case series demonstrated a very impressive effect of the new block on the dynamic pain score. With the better understanding of the anatomy for hip innervation<sup>15</sup> and the planes where the nerves to the hip innervation run,<sup>15,18</sup> this case series may help researchers to consider a new approach of nerve block for patients with hip fracture. Larger studies need to be conducted to compare the efficacy of this new technique with that of the more established regional techniques for hip analgesia, as well

as anatomic studies to confirm the spread of local anesthetics and the nerves targeted.

## REFERENCES

1. Brauer CA, Coca-Perraillon M, Cutler DM, Rosen AB. Incidence and mortality of hip fractures in the United States. *JAMA*. 2009;302:1573–1579.
2. Neuman MD, Fleisher LA, Even-Shoshan O, Mi L, Silber JH. Nonoperative care for hip fracture in the elderly: the influence of race, income, and comorbidities. *Med Care*. 2010;48:314–320.
3. Morrison RS, Magaziner J, Gilbert M, et al. Relationship between pain and opioid analgesics on the development of delirium following hip fracture. *J Gerontol A Biol Sci Med Sci*. 2003;58:76–81.
4. Morrison RS, Magaziner J, McLaughlin MA, et al. The impact of post-operative pain on outcomes following hip fracture. *Pain*. 2003;103:303–311.
5. Foss NB, Kristensen BB, Bundgaard M, et al. Fascia iliaca compartment blockade for acute pain control in hip fracture patients: a randomized, placebo-controlled trial. *Anesthesiology*. 2007;106:773–778. Haines L, Dickman E, Ayvazyan S, Pearl M, Wu S, Rosenblum D, et al. Ultrasound-guided fascia iliaca compartment block for hip fractures in the emergency department. *J Emerg Med*. 2012;43:692–697.
6. Unneby A, Svensson O, Gustafson Y, Olofsson B. Femoral nerve block in a representative sample of elderly people with hip fracture: a randomised controlled trial. *Injury*. 2017;48:1542–1549.
7. Beaudoin FL, Haran JP, Liebmann O. A comparison of ultrasound-guided three-in-one femoral nerve block versus parenteral opioids alone for analgesia in emergency department patients with hip fractures: a randomized controlled trial. *Acad Emerg Med*. 2013;20:584–591.
8. Guay J, Parker MJ, Griffiths R, Kopp S. Peripheral nerve blocks for hip fractures. *Cochrane Database Syst Rev*. 2017;5:CD001159.

9. Marhofer P, Nasel C, Sitzwohl C, Kapral S. Magnetic resonance imaging of the distribution of local anesthetic during the three-in-one block. *Anesth Analg*. 2000;90:119–124.
10. Swenson JD, Davis JJ, Stream JO, Crim JR, Burks RT, Greis PE. Local anesthetic injection deep to the fascia iliaca at the level of the inguinal ligament: the pattern of distribution and effects on the obturator nerve. *J Clin Anesth*. 2015;27:652–657.
11. Wertheimer LG. The sensory nerves of hip joint. *J Bone Joint Surg Am*. 1952;34-A:477–487.
12. Birnbaum K, Prescher A, Hessler S, Heller KD. The sensory innervation of the hip joint—an anatomical study. *Surg Radiol Anat*. 1997;19:371–375.
13. Gardner E. The innervation of the hip joint. *Anat Rec*. 1948;101:353–371.
14. Gerhardt M, Johnson K, Atkinson R, et al. Characterisation and classification of the neural anatomy in the human hip joint. *Hip Int*. 2012; 22:75–81.
15. Short AJ, Barnett JGG, Gofeld M, et al. Anatomic study of innervation of the anterior hip capsule: implication for image-guided intervention. *Reg Anesth Pain Med*. 2018;43:186–192.
16. Bhatia A, Hoydonckx Y, Peng P, Cohen SP. Radiofrequency procedures to relieve chronic hip pain. An evidence-based narrative review. *Reg Anesth Pain Med*. 2018;43:72–83.
17. Archana BJ, Nagaraj DN, Pradeep P, Lakshmi Prabha S. Anatomic variations of accessory obturator nerve: a cadaveric study with proposed clinical implications. *Int J Anat Res*. 2016;4:2158–2161.
18. Nielsen TD, Moriggl B, Soballe K, Kolsen-Petersen JA, Børglum J, Bendtsen TF. A cadaveric study of ultrasound-guided subpectineal injectate spread around the obturator nerve and its hip articular branches. *Reg Anesth Pain Med*. 2017;42:357–361.
19. Nissen T, Wynn R. The clinical case report: a review of its merits and limitations. *BMC Res Notes*. 2014;7:264.