

Point-of-care biliary ultrasound in the emergency department (BUSED): implications for surgical referral and emergency department wait times

Richard Hilsden,¹ Rob Leeper,^{1,2} Jennifer Koichopolos,¹ Jeremy Derek Vandelinde,³ Neil Parry,^{1,2} Drew Thompson,⁴ Frank Myslik⁴

¹Department of Surgery, Western University, London, Ontario, Canada

²Division of Critical Care Medicine, Western University, London, Ontario, Canada

³Schulich School of Medicine and Dentistry, Western University, London, Ontario, Canada

⁴Division of Emergency Medicine, Western University, London, Ontario, Canada

Correspondence to

Dr Richard Hilsden, Department of Surgery, Western University, London, ON N6A 5A5, Canada; richard.hilsden@londonhospitals.ca

Received 18 January 2018

Revised 24 May 2018

Accepted 5 June 2018

ABSTRACT

Background Patients with uncomplicated biliary disease frequently present to the emergency department for assessment. To improve bedside clinical decision making, biliary point-of-care ultrasound (POCUS) in the emergency department has emerged as a diagnostic tool. The purpose of this study is to analyze the usefulness of POCUS in predicting the need for surgical intervention in biliary disease.

Methods A retrospective study of patients visiting the emergency department who received a biliary POCUS from December 1, 2016 to July 15, 2017 was performed. The physician interpretations of the biliary POCUS scans were collected, as well as data from the electronic health records including lab values, the subsequent use of diagnostic imaging, surgical consultation or intervention, and 28 days follow-up for representation or complication.

Results Two hundred and eighty-three patients were identified as having received biliary POCUS. Of the patients referred to general surgery who received biliary POCUS 43% received a cholecystectomy. For the outcome of cholecystectomy, the finding of gallstones on POCUS was 55% sensitive (95% CI 40% to 70%) and 92% specific (95% CI 87% to 95%). A sonographic Murphy's sign was 16% sensitive (95% CI 7% to 30%) but 95% specific (95% CI 92% to 97%) and, gallbladder wall thickness was 18% sensitive (95% CI 9% to 33%) and 98% specific (95% CI 95% to 99%). Patients who received POCUS but did not proceed to confirmatory radiology department imaging had a shorter length of stay (433 min \pm 50 min vs. 309 min \pm 30 min, $P < 0.001$).

Discussion Point-of-care biliary ultrasound performed by emergency physicians provides timely access to diagnostic information. Positive findings of gallstones and increased gallbladder wall thickness are highly predictive of the need for surgical intervention, and use of POCUS is associated with shorter ER visits.

Level of evidence Retrospective cohort study, level III.

INTRODUCTION

Gallbladder disease affects over 20 million Americans annually.¹ Acute cholecystitis accounts for 3% to 11% of hospital admissions^{2–4} and is associated with a mortality rate of 0.8%.⁵ Point-of-care ultrasound (POCUS) in the emergency department has the potential to become an integral step to accelerate the diagnosis and management of gallbladder disease.

Multiple studies have examined the diagnostic accuracy of history, physical examination, and laboratory tests for cholecystitis⁶ and a meta-analysis quantitatively showed that POCUS consistently surpassed all other bedside investigations for sensitivity for the diagnosis of biliary disease.⁷ Additionally, POCUS has been studied for accuracy with a recent systematic review showing the sensitivity and specificity for cholelithiasis is 89.8% and 88.0%, respectively.⁸ POCUS has also been assessed for the diagnosis of acute cholecystitis and found to be highly sensitive and specific (87% and 82%) when the criteria of gallstones plus an additional finding of a sonographic Murphy's sign, gallbladder wall thickness, or pericholecystic fluid is used for assessment.^{9–10} Results of POCUS for biliary disease have been shown to be similarly accurate to findings of radiologist performed ultrasounds (sensitivity 83% and specificity 86%).⁹

Furthermore, targeted abdominal POCUS is quick and easy to perform with 83% percent of emergency studies being completed in less than 10 minutes.¹¹ It can also be easily taught to learners. After a focused training course, novice ultrasound users with no prior ultrasound experience were able to attain moderate to perfect degree of agreement with experienced radiologists when looking at characteristics of biliary ultrasound.¹² POCUS is also effective in decreasing the length of stay of patients in the emergency department when compared with those who received a radiologist performed ultrasound with the length of stay decreasing by 11% during daytime hours and up to 20% during afterhours.¹³

Despite this growing body of evidence demonstrating the favourable diagnostic performance characteristics of point-of-care biliary ultrasound, a gap appears to remain between emergency room (ER) diagnosis and surgical management.^{14–15} Concerns remain regarding the need for confirmatory radiology-based testing prior to operating on the gallbladder and skepticism remains regarding the diagnostic utility of biliary POCUS outside a controlled research setting.¹⁶ The goal of this study is to evaluate the predictive value of biliary POCUS during its routine application in a tertiary care emergency department in terms of the need for cholecystectomy and its impact on the patient experience.

METHODS

A retrospective cohort study was performed to analyze the performance characteristics of biliary

To cite: Hilsden R, Leeper R, Koichopolos J, et al. *Trauma Surg Acute Care Open* 2018;3:e000164.

POCUS utilization for abdominal complaints in a tertiary care hospital environment. As part of routine care, emergency medicine providers in our institution (with additional training in POCUS) frequently use point-of-care biliary imaging to evaluate abdominal complaints. These ER physicians are expected to record the dynamic ultrasound images on a commercially available, cloud-based system (Qpath, Telexy Healthcare Inc.) at the time of image acquisition. This system is designed for quality assurance and billing purposes. Providers are also required to record their interpretation either on the electronic image itself or on an electronic form that is associated with the ultrasound images that may be completed at a later time during the patient encounter. Institutional research ethics board approval was obtained prior to the initiation of this research.

The ER providers in our institution who regularly use biliary ultrasound in their practice were identified. Each of these providers met the American College of Emergency Physicians guidelines for competency in the biliary application of POCUS.¹⁷ For the study period of December 1, 2016 to July 2017, all adult patients who received a point-of-care biliary ultrasound by these providers were identified for evaluation. The exclusion criteria were patients under the age of 18 years, and patients who were identified as having point-of-care imaging but did not have biliary images recorded for subsequent review.

All biliary images were then evaluated by a reviewer who was fellowship trained in emergency department ultrasound imaging. This reviewer abstracted the following characteristics from the gallbladder imaging: number of gallbladder views, presence of gallstones, presence of pericholecystic fluid, visualization of the common bile duct, visualization of gallbladder neck, gallbladder wall thickness, and the presence or absence of a sonographic Murphy's sign. For the purposes of our analysis the gallbladder wall was considered thick if the gallbladder wall was greater than 4 mm or the ultrasound provider indicated in the medical record that, in their opinion, the gallbladder wall was thickened. The electronic medical record was reviewed in addition to the paper record to identify the discharge diagnosis, results of any formal abdominal imaging, the results of any biochemical tests performed, referrals, disposition from the emergency department, the length of stay in the emergency department, and what, if any, surgical procedures were ultimately performed.

The primary outcome evaluated was the diagnostic performance of a biliary POCUS assessment in its ability to predict the need for eventual cholecystectomy. We report this outcome as a sensitivity and specificity with a patient ultimately proceeding to cholecystectomy as a true positive. Secondary outcomes included an evaluation of the ultrasound parameters predictive of the need for cholecystectomy, the providers' decision to obtain radiology-based ultrasound imaging, and referrals to specialty services. Patient experience outcomes included likelihood of return to the emergency department with abdominal pain, and length of stay in the emergency department. The prespecified ultrasound parameters included in this secondary analysis were: presence of gallstones, presence of pericholecystic fluid, the presence of gallbladder wall thickening, the presence of a sonographic Murphy's sign, and the presence of biliary tree dilation. For the purposes of estimating sensitivity and specificity, as well as for multivariate analysis, when an interpretation of a relevant gallbladder feature was missing (such as gallbladder wall thickness or presence or absence of pericholecystic fluid), the feature was assumed to be negative to account for an assumed bias in recording positive features on the ultrasound images over negative features.

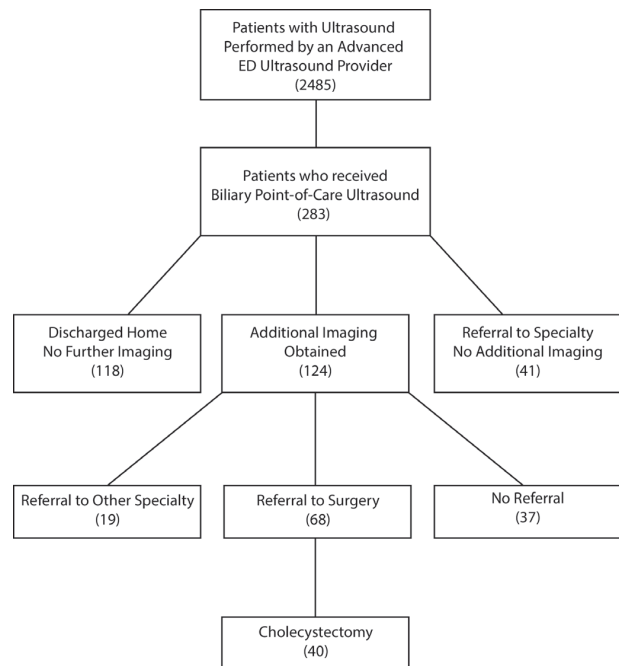


Figure 1 Cohort flow diagram.

Statistical tests were performed in SPSS version 24. Student's t-test was performed for continuous variables, χ^2 test was performed for categorical variables, and a multivariate logistic regression was performed to analyze the ultrasound parameters independently predictive of the abovementioned secondary outcomes.

RESULTS

Eight providers with additional training in biliary POCUS were identified and approached to participate in this research, and all eight agreed to contribute patients. During the study period these providers performed biliary POCUS on 283 patients (figure 1). Of the patients who received biliary POCUS 29% were referred for evaluation by general surgery. Among the patients referred to general surgery 43% ultimately went on to receive a cholecystectomy.

Retrospective review of the imaging recorded for quality assurance purposes demonstrated that 49% of the images had annotations made regarding the presence or absence of gallstones. In 16% of the images, gallstones were indicated as present. In 51% of patients, gallbladder wall thickness was commented on by the point-of-care provider, and 6% of patients were reported as having gallbladder wall thickening. Only in 25% of patients did the provider comment on the presence or absence of a sonographic Murphy's sign, with 6% overall being identified as having a positive sonographic Murphy's sign. Finally, in 25% of patients comments were made regarding pericholecystic fluid with only one patient (0%) having pericholecystic fluid identified. None of the providers reported on gallbladder wall hyperemia (table 1).

Chart review identified surgical outcomes for many of the patients referred. Specifically, 43% of the patients who had biliary POCUS and were referred to general surgery ultimately had a cholecystectomy performed. All but two patients (5%) underwent radiology department imaging prior to receiving a cholecystectomy. Regarding all operations, a patient who had a

Table 1 Proportion of patients with significant findings

	n (%)
Total	283 (100)
Gallstones present	44 (16)
Wall thickening	18 (6)
Sonographic Murphy's sign	18 (6)
Pericholecystic fluid	1 (0)
CBD dilation	3 (1)
Referred to formal imaging	124 (30)

CBD, common bile duct.

biliary POCUS, and was referred to a surgical service, had 61% chance of eventually proceeding to surgery.

The diagnostic performance of biliary POCUS was evaluated with the eventual need for cholecystectomy treated as the gold standard. By this criterion the presence of gallstones on POCUS was 55% sensitive (95% CI 40% to 70%) and 92% specific (95% CI 87% to 95%). Similarly, sonographic Murphy's sign was 16% sensitive (95% CI 7% to 30%) but 95% specific (95% CI 92% to 97%) and, finally, gallbladder wall thickness was 18% sensitive (95% CI 9% to 33%) and 98% specific (95% CI 95% to 99%). The presence of any of the above findings resulted in a sensitivity of 63% (95% CI 48% to 78%) and a specificity of 89% (95% CI 84% to 93%). On review of the pathologic specimens 100% of patients who had a cholecystectomy in our cohort had pathologic evidence of cholecystitis. Only three patients who had a cholecystectomy did not have gallstones on the pathologic specimen and in each of these patients the biliary POCUS showed no gallstones present (table 2).

Multivariate logistic regression was performed to identify the POCUS features independently associated with gallbladder surgery (table 3). The presence of gallstones resulted in an OR 13.14 ($P<0.001$, 95% CI 5.59 to 30.89) and was the strongest predictor of surgery among biliary POCUS patients. The presence of gallbladder wall thickness was associated with an OR of 4.815 ($P=0.017$, 95% CI 1.33 to 17.438). The presence of a sonographic Murphy's sign (OR 2.675, $P=0.185$, 95% CI 0.625 to 11.453). The only characteristic which did not reach significance was the presence of biliary tree dilatation (OR 10.632, $P=0.087$, 95% CI 0.711 to 158.8).

Regarding the outcome of a return to the emergency department with abdominal pain, the same POCUS features were evaluated. The only ultrasound feature independently associated with an unexpected return to the ER was the presence of biliary tree dilation with an OR of 33.67 ($P=0.019$, 95% CI 1.8 to 630.7, table 4). Ultrasound features were also evaluated to analyze their ability to predict the need for subsequent formal ultrasound performed in the radiology department. None of the prespecified sonographic criteria were found to be independently associated with subsequent performance of radiology-based ultrasound (table 5).

Table 2 Diagnostic performance of individual point-of-care ultrasound features

	Sensitivity % (95% CI)	Specificity % (95% CI)
Gallstones present	0.55 (0.40 to 0.70)	0.92 (0.88 to 0.95)
Sonographic Murphy's sign	0.66 (0.57 to 0.77)	0.95 (0.92 to 0.98)
Thickened gallbladder wall	0.18 (0.6 to 0.29)	0.98 (0.96 to 1.00)
Any positive feature	0.63 (0.48 to 0.78)	0.89 (0.84 to 0.93)

Table 3 Point-of-care ultrasound findings predictive of gallbladder surgery

	OR	P values	95% CI for OR
Gallstone present	13.141	0.000	5.590 30.890
Sonographic Murphy's sign	2.675	0.185	0.625 11.453
Pericholecystic fluid	0.000	1.000	0.000 –
Biliary tree dilation	10.632	0.087	0.711 158.883
Gallbladder wall thickening	4.815	0.017	1.330 17.438
Constant	0.026	0.000	
R-Squared	0.177		

Finally, there was a significant difference in length of stay in the emergency department between the patients referred for radiology-based imaging compared with those who had a POCUS image alone and were discharged (433 minutes \pm 50 minutes vs. 309 minutes \pm 30 minutes, $P<0.001$). Looking only at patients who were discharged from the emergency department but who were asked to return to the hospital for radiology-based imaging, their length of time to diagnostic completion was a significantly longer 968 minutes (95% CI 774 minutes to 1110 minutes, $P<-0.001$).

DISCUSSION

Our study is the first to report the impact of routine use of POCUS on the care of patients with biliary disease. From the perspective of diagnostic test performance our results are consistent with the literature in demonstrating that the use of biliary POCUS is sensitive and specific for assessing the presence of cholelithiasis, as well as features of cholecystitis.^{18 19} Uniquely, we chose to use the need for cholecystectomy as the gold standard by which our diagnostic test was evaluated. We chose this outcome as it is the ultimate treatment disposition for patients with biliary disease that is of most interest to surgeons and their patients. This is in contrast with typical validation studies of POCUS which compare the results of the bedside test with radiology department ultrasound. As a result, this study is the first to demonstrate that the presence of gallstones found on a POCUS scan in a patient with a significant suspicion for biliary pathology is highly predictive of the eventual need for cholecystectomy. Currently, surgeons are unlikely to take a patient for a cholecystectomy on a positive biliary POCUS study alone, instead relying on confirmatory ultrasounds performed in the radiology department.^{14 20} Despite significant evidence demonstrating good sensitivities and specificities of POCUS in the diagnosis of cholelithiasis,⁸ a gap

Table 4 Point-of-care ultrasound findings predictive of return to emergency room with abdominal pain

	OR	P values	95% CI for OR
Gallstone present	1.570	0.439	0.502 4.912
Sonographic Murphy's sign	2.808	0.384	0.275 28.645
Pericholecystic fluid	0.000	1.000	0.000 –
Biliary tree dilation	33.697	.019	1.800 630.771
Gallbladder wall thickening	1.470	0.652	0.276 7.844
Constant	0.032	0.004	
R-Squared	0.026		

Table 5 Point-of-care findings predictive of return to emergency room for formal ultrasound

	OR	P values	95% CI for OR	
Gallstone present	1.878	0.162	0.776	4.544
Sonographic Murphy's sign	1.297	0.732	0.293	5.743
Pericholecystic fluid	14236755018.553	1.000	0.000	–
Biliary tree dilation	0.000	0.999	0.000	–
Gallbladder wall thickening	1.987	0.275	0.579	6.822
Constant	0.113	0.005		
R-Squared	0.031			

between this evidence and surgical decision making remains, owing potentially to a perceived lack of trust in biliary POCUS.¹⁴ We propose that in a patient with right upper quadrant abdominal pain that is consistent with biliary disease (gradual onset, constant, and unremitting), without a high-risk feature (clinical jaundice or elevated bilirubin) and without more likely alternative diagnosis (eg, peptic ulcer disease), surgeons consider offering the patient a cholecystectomy on the POCUS findings of biliary disease without confirmatory imaging. We also think that those patients with concerning features or inconsistent history and physical examinations be evaluated with formal radiology department imaging prior to operating. To further support this management strategy we suggest further research be conducted in the form a prospective study design.

In this study, we reported on the proportion of cases in which the POCUS documentation commented on the presence or absence of gallstones, and it was found that only half (49%) of scans mentioned this finding, with 16% being reported as positive. In addition, the presence of a gallstone on a POCUS study in the ER was the most significant feature predicting the eventual need for cholecystectomy. This rate of incomplete documentation, combined with the importance of these specific findings, may represent a barrier to acceptance of biliary POCUS among surgeons and is an area requiring further study. In addition to the predictive value of positive biliary POCUS studies regarding operative management, emergency department ultrasound demonstrated value with respect to the rates of referral to surgical specialties. Of the patients who received a biliary ultrasound in the emergency department (BUSED) study, 29% were referred to general surgery. Forty-three percent of those referrals ended up receiving a cholecystectomy. Since nearly half of the referrals who had a biliary POCUS were ultimately treated surgically, this research supports the concept that point-of-care biliary ultrasound may increase both the threshold for surgical referral and the accuracy of referral, potentially saving resources.²¹

Additional potential benefits of accepting positive POCUS scans as an indication for surgery in the absence of confirmatory imaging include the reduced healthcare costs and improved patient experience. The majority of patients in this study (95%) received radiology department imaging (either ultrasound or CT scan) prior to proceeding to cholecystectomy. This additional imaging took time and often patients were sent home to return for the imaging study (33% had to return for imaging). Many of these patients had a positive ultrasound study due to the presence of gallstones, the highest predictor of the eventual need for surgery. We propose that, in the correct patient population,

the additional step of radiology-performed ultrasound is unnecessary based on our findings of excellent sensitivity and specificity for biliary POCUS, a finding that is consistent with the literature.^{18, 19} Surgeons acting on the results of an emergency department ultrasound could potentially save the patients' time in the department as well as reduce the overall time for a definitive diagnosis. We have shown that those patients who received additional imaging waited an average 11 hours longer than those who were diagnosed on BUSED alone. Biliary disease is painful and by saving time for these patients we can reduce their suffering and improve their overall experience.

There are several potential limitations of this study. As with all retrospective research, this study is at risk of bias since it is impossible to exclude the possibility that in some patients the ER providers may have documented their findings in the chart after they received feedback from their surgical colleague. The second limitation was assumption that the provider thought a finding was negative (or within normal range) if no comments were made in the medical record. It is certainly possible that an abnormality was noted, and acted on but not recorded therefore influencing our diagnostic accuracy calculations. Finally, this retrospective study is at risk of selection bias if the ER providers only chose to save the images on patients where the image quality was high and the probability of missing an important feature of the biliary examination was low. This could potentially falsely improve our diagnostic accuracy estimates.

Future steps that could stem from this research include an analysis of the attitudes of practising surgeons regarding the use of POCUS in diagnosing biliary disease. This could be assessed using a survey that identifies key factors analyzing the surgeon's willingness to take the patient to the operating room. Factors may include the surgeon's experience with POCUS, perceived training and expertise of the ER providers at their institution as well as medicolegal considerations. Finally, unlike in the case of focused assessment by sonography for trauma, the literature is lacking any high-quality prospective studies that evaluate the effectiveness of surgical strategy relying on point-of-care imaging for operative decision making in biliary disease. Such an evaluation would have the potential to influence the standard of care, improving healthcare resource utilization and simultaneously improving overall patient experience.

Contributors RH, FM, RL, DT, and NP conceptualized, designed, supervised, and allocated resources for this research. JDV, JK, and FM completed the data collection. RH and JDV performed the statistical analysis. All authors contributed to the analysis of the results. All authors contributed to the writing of the final article text.

Funding The authors have not declared a specific grant for this research from any funding agency in the public, commercial or not-for-profit sectors.

Competing interests None declared.

Patient consent Not required.

Ethics University of Western Ontario research ethics board.

Provenance and peer review Not commissioned; externally peer reviewed.

Open access This is an Open access article distributed in accordance with the Creative Commons Attribution Non Commercial (CC BY-NC 4.0) license, which permits others to distribute, remix, adapt, build upon this work non-commercially, and license their derivative works on different terms, provided the original work is properly cited, appropriate credit is given, any changes made indicated, and the use is non-commercial. See: <http://creativecommons.org/licenses/by-nc/4.0/>.

© Author(s) (or their employer(s)) 2018. Re-use permitted under CC BY-NC. No commercial re-use. See rights and permissions. Published by BMJ.

REFERENCES

- 1 Everhart JE, Khare M, Hill M, Maurer KR. Prevalence and ethnic differences in gallbladder disease in the United States. *Gastroenterology* 1999;117:632–9.

- 2 Hastings RS, Powers RD. Abdominal pain in the ED: a 35 year retrospective. *Am J Emerg Med* 2011;29:711–6.
- 3 Miettinen P, Pasanen P, Lahtinen J, Alhava E. Acute abdominal pain in adults. *Ann Chir Gynaecol* 1996;85:5–9.
- 4 Irvin TT. Abdominal pain: a surgical audit of 1190 emergency admissions. *Br J Surg* 1989;76:1121–5.
- 5 Udekwo PO, Sullivan WG. Contemporary experience with cholecystectomy: establishing 'benchmarks' two decades after the introduction of laparoscopic cholecystectomy. *Am Surg* 2013;79:1253–7.
- 6 Trowbridge RL, Rutkowski NK, Shojania KG. Does this patient have acute cholecystitis? *JAMA* 2003;289:80–6.
- 7 Jain A, Mehta N, Secko M, Schechter J, Papanagnou D, Pandya S, Sinert R. History, physical examination, laboratory testing, and emergency department ultrasonography for the diagnosis of acute cholecystitis. *Acad Emerg Med* 2017;24:281–97.
- 8 Ross M, Brown M, McLaughlin K, Atkinson P, Thompson J, Powelson S, Clark S, Lang E. Emergency physician-performed ultrasound to diagnose cholelithiasis: a systematic review. *Acad Emerg Med* 2011;18:227–35.
- 9 Summers SM, Scruggs W, Menchine MD, Lahham S, Anderson C, Amr O, Lotfipour S, Cusick SS, Fox JC. A prospective evaluation of emergency department bedside ultrasonography for the detection of acute cholecystitis. *Ann Emerg Med* ; 2010;56:114–22.
- 10 Villar J, Summers SM, Menchine MD, Fox JC, Wang R. The absence of gallstones on point-of-care ultrasound rules out acute cholecystitis. *J Emerg Med* ; 2015;49:475–80.
- 11 Kendall JL, Shimp RJ. Performance and interpretation of focused right upper quadrant ultrasound by emergency physicians. https://journals-scholarsportal-info.proxy1.lib.uwo.ca/pdf/07364679/v21i0001/7_paiofruqubep.xml (cited 28 Dec 2017).
- 12 Seyedhosseini J, Nasrelari A, Mohammadrezaei N, Karimialavijeh E. Inter-rater agreement between trained emergency medicine residents and radiologists in the examination of gallbladder and common bile duct by ultrasonography. <https://link-springer-com.proxy1.lib.uwo.ca/content/pdf/10.1007%2Fs10140-016-1468-0.pdf> (cited 25 Dec 2017).
- 13 Blaivas M, Harwood RA, Lambert MJ. Decreasing length of stay with emergency ultrasound examination of the gallbladder. *Acad Emerg Med* 1999;6:1020–3.
- 14 Hansen W, Mitchell CE, Bhattarai B, Ayutyanont N, Stowell JR. Perception of point-of-care ultrasound performed by emergency medicine physicians. *J Clin Ultrasound* 2017;45:408–15.
- 15 Thomson SR, Krige JEJ. No longer HOCUS POCUS. The time has come for surgeons to embrace point of care ultrasound training. *South African J Surg* 2016;54:2–3.
- 16 Shah S, Bellows BA, Adedipe AA, Totten JE, Backlund BH, Sajed D. Perceived barriers in the use of ultrasound in developing countries. *Crit Ultrasound J* 2015;7:11.
- 17 Ultrasound guidelines: emergency, point-of-care, and clinical ultrasound guidelines in medicine. 2016. https://www.acep.org/Clinical-Practice-Management/Ultrasound-Guidelines-Emergency,-Point-of-care,-and-Clinical-Ultrasound-Guidelines-in-Medicine/?__taxonomyid=471332
- 18 Carroll PJ, Gibson D, El-Faedy O, Dunne C, Coffey C, Hannigan A, Walsh SR. Surgeon-performed ultrasound at the bedside for the detection of appendicitis and gallstones: systematic review and meta-analysis. *Am J Surg* 2013;205:102–8.
- 19 Gustafsson C, McNicholas A, Sonden A, Törngren S, Järnbert-Pettersson H, Lindelius A. Accuracy of surgeon-performed ultrasound in detecting gallstones: a validation study. *World J Surg* 2016;40:1688–94.
- 20 Lim N, McCabe A, Cronin J. Use of emergency department point-of-care ultrasound in a case of cholecystitis. *BMJ Case Rep* 2017;2017.
- 21 Burton CD, McLernon DJ, Lee AJ, Murchie P. Distinguishing variation in referral accuracy from referral threshold: analysis of a national dataset of referrals for suspected cancer. *BMJ Open* 2017;7:e016439.