

A Prospective Evaluation of Point-of-Care Ultrasonographic Diagnosis of Diverticulitis in the Emergency Department

Allison Cohen, MD*; Timmy Li, PhD; Brendon Stankard, RPA-C; Mathew Nelson, DO

*Corresponding author. E-mail: acohen20@northwell.edu, Twitter: @acohen424.

Study objective: We evaluate the sensitivity and specificity of point-of-care ultrasonography, performed by ultrasonographic fellowship-trained emergency physicians and physician assistants, compared with computed tomography (CT) scan in diagnosing acute diverticulitis in the emergency department (ED).

Methods: This was a prospective observational study of a convenience sample of patients with suspected diverticulitis who were treated at an academic ED between 2017 and 2020. Sonographers were blinded to clinical data, laboratory results, and CT scan findings. A total of 19 ultrasonographic fellowship-trained emergency physicians and physician assistants performed the ultrasonographic examinations. Point-of-care ultrasonographic diagnosis of acute diverticulitis was defined as the presence of bowel wall thickening, greater than 5 mm, surrounding a diverticulum, enhancement of the surrounding pericolonic fat, and sonographic tenderness to palpation. The primary outcome measures were sensitivity, specificity, positive predictive value, and negative predictive value of point-of-care ultrasonography in the diagnosis of diverticulitis compared with CT, which was considered the criterion standard.

Results: Data from 452 patients were analyzed. Median age was 60 years, 54% were women, and 36% had a diagnosis of diverticulitis based on CT scan. Of the 452 patients, there were 13 false-positive (3%) and 10 false-negative (2%) point-of-care ultrasonographic examinations. Overall, compared with CT, point-of-care ultrasonography had a sensitivity of 92% (95% confidence interval 88% to 96%), specificity of 97% (95% confidence interval 94% to 99%), positive predictive value of 94% (95% confidence interval 90% to 97%), and negative predictive value of 96% (93% to 98%) in the diagnosis of diverticulitis.

Conclusion: In a convenience sample of ED patients with suspected diverticulitis, point-of-care ultrasonography performed by ultrasonographic fellowship-trained emergency physicians and physician assistants could be used as an imaging modality for diagnosing acute diverticulitis, with high sensitivity and specificity compared with CT scan. [Ann Emerg Med. 2020;■:1-10.]

Please see page XX for the Editor's Capsule Summary of this article.

0196-0644/\$-see front matter

Copyright © 2020 by the American College of Emergency Physicians.

<https://doi.org/10.1016/j.annemergmed.2020.05.017>

INTRODUCTION

Background

Diverticulitis is a common diagnosis in the emergency department (ED), resulting from inflammation of colonic diverticula. Acute diverticulitis develops in approximately 10% to 20% of patients with diverticulosis and is reported as the second leading cause of abdominal pain, resulting in greater than 130,000 annual hospital admissions in the United States.¹⁻³ Approximately 10% of diverticulitis cases occur in patients younger than 40 years.^{4,5} Diverticulitis commonly presents with a constellation of nonspecific symptoms, including diarrhea, fever, and abdominal pain, making it challenging to diagnose.⁶

Importance

It has been estimated that approximately one third of patients with acute diverticulitis receive misdiagnoses on initial clinical presentation, highlighting the importance of imaging to improve diagnosis.⁷ Currently, computed tomography (CT) is the imaging modality of choice for patients with suspected diverticulitis because of its high sensitivity and specificity, and an overall accuracy of 99%.^{8,9} Although a CT scan is commonly ordered to evaluate these patients, concerns of reported radiation exposure as well as increased length of stay in the ED have led to the increased use of ultrasonography in evaluating these patients. Point-of-care ultrasonography is commonly performed in the ED to evaluate patients presenting with

Editor's Capsule Summary*What is already known on this topic*

Point-of-care ultrasonography has shown moderate to excellent sensitivity in diagnosing diverticulitis, but information about its utility in the emergency department (ED) is limited

What question this study addressed

In ED patients with suspected diverticulitis, how does point-of-care ultrasonography compare with the criterion standard of computed tomography (CT)?

What this study adds to our knowledge

In this prospective observational study, 452 patients who underwent abdominal CT for suspected diverticulitis also underwent point-of-care ultrasonography. Sensitivity was 92% and specificity 97%; 23% of patients with positive results had complicated diverticulitis.

How this is relevant to clinical practice

Point-of-care ultrasonography may be useful in diagnosing uncomplicated diverticulitis, but it is operator dependent, and many patients may still undergo CT. How well point-of-care ultrasonography can identify complicated diverticulitis, which may require more aggressive acute management, remains unclear.

undifferentiated abdominal pain and is commonly used to evaluate for free fluid in trauma patients, pregnancy complications, gallbladder disease, bowel obstructions, and identification of abdominal aortic aneurysms.¹⁰⁻¹² It has been shown in previous studies to have sensitivities ranging from 77% to 98% in diagnosing diverticulitis.^{4,13-17} However, it is not commonly performed in EDs in the United States.^{6,14} Although the use of point-of-care ultrasonography to diagnose diverticulitis has been reported in the surgical literature, limited studies have focused on its use in the ED setting. To our knowledge, there have been no large-scale prospective studies evaluating the sensitivity and specificity of point-of-care ultrasonography, performed by emergency physicians, in diagnosing diverticulitis in the ED setting. If physicians were able to rapidly make the diagnosis of acute diverticulitis at the bedside in the ED, it could reduce patients' ED length of stay because they would not need to wait for CT scan, decrease ionizing radiation exposure, and lead to earlier administration of antibiotic treatment.

Goals of This Investigation

The goal of this study was to evaluate the test characteristics, including sensitivity, specificity, positive predictive value, and negative predictive value, of point-of-care ultrasonography in the diagnosis of diverticulitis in the ED compared with the criterion standard of CT scan. We hypothesized that point-of-care ultrasonography would have high specificity and sensitivity in diagnosing diverticulitis.

MATERIALS AND METHODS**Study Design and Setting**

This was a prospective study of a convenience sample of patients treated at the ED of North Shore University Hospital in Manhasset, NY, between September 2017 and January 2020. North Shore University Hospital is a 738-bed quaternary care facility with an ED census of approximately 90,000 patients per year. It is an American College of Surgeons–verified Level I trauma center with an established emergency medicine residency program and an emergency ultrasonographic fellowship training program. This study was approved by the Northwell Health system's institutional review board and all patients provided written informed consent.

Selection of Participants

A convenience sample of patients was enrolled in this study. Study personnel, who consisted of ultrasonographic fellowship–trained faculty members and ultrasonographic fellows, screened the tracking board of the electronic health record system to identify ED patients with a chief complaint of abdominal pain. They then approached the treating physicians and asked whether they were considering diverticulitis in their differential diagnosis as the cause of the patient's symptoms and whether they were planning to order an abdominal CT scan to confirm the diagnosis. Additionally, all faculty, residents, and nursing staff were alerted to the study and instructed to call study personnel if they thought they had an eligible patient. Patients were eligible for study participation if they presented with abdominal pain associated with suspicion for diverticulitis and the emergency physician planned to order an abdominal CT scan. Exclusion criteria included clinical instability (at the discretion of the treating physician), pregnancy, younger than 18 years, abdominal surgery within the previous 2 weeks, a preconfirmed diagnosis of diverticulitis, unable to consent, or no CT scan during the ED visit. Enrollment occurred primarily on weekdays during ultrasonographic scanning shifts, when there are designated ultrasonographic faculty members or

ultrasonographic fellows available to perform scans. However, if study personnel were available on alternate dates, they could approach the physician to enroll the patient if he or she met eligibility criteria. The majority of patients were enrolled during weekday business hours. Patients provided consent before a CT scan was obtained, and ultrasonographic images were obtained before the patient received a CT scan.

Data Collection and Processing

The sonographer performing the point-of-care ultrasonographic examination was either an ultrasonographic fellow or an ultrasonographic fellowship-trained emergency physician or physician assistant. All sonographers participated in a 40-minute didactic training course before enrolling subjects, which consisted of reviewing positive and negative image results, ultrasonographic criteria for the diagnosis, and information on study protocol. The principal investigator (A.C.) trained all study sonographers and performed 5 precepted scans with each sonographer, requiring at least 1 of these scans to be positive for diverticulitis. Sonographers were blinded to patient clinical data and radiologic imaging, and were separate from the clinical team caring for the patient. Treating clinicians and patients remained blinded to results of the point-of-care ultrasonographic examination. Ultrasonography was performed by 5 ultrasonographic fellowship-trained faculty members and 14 ultrasonographic fellows during 2.5 years.

The ultrasonographic protocol consisted of scanning a supine patient using a Zonare Z.One Pro (Zonare Medical Systems Inc, Mountain View, CA) ultrasound system with a curvilinear transducer (either C6-2 or C4-1 MHz) on focused assessment of sonography in trauma (FAST) knobology presets. The scan was initiated at the patient's point of maximum tenderness. Graded compression was used to enhance visualization of the bowel. The entire abdomen was scanned with the "lawn mower" technique,¹⁸ which consisted of starting at the point of maximum tenderness and moving the ultrasonographic transducer, using grading compression, in a vertical pattern across the abdomen to evaluate the entire bowel.

Criteria for a positive point-of-care ultrasonographic examination result were based on previously reported findings of sonographic features of acute diverticulitis.⁶ Diverticulitis was determined to be present if all of the following were observed on the point-of-care ultrasonographic examination: bowel wall edema greater than 5 mm and surrounding a diverticula, enhancement of the surrounding pericolonic fat (indicating associated

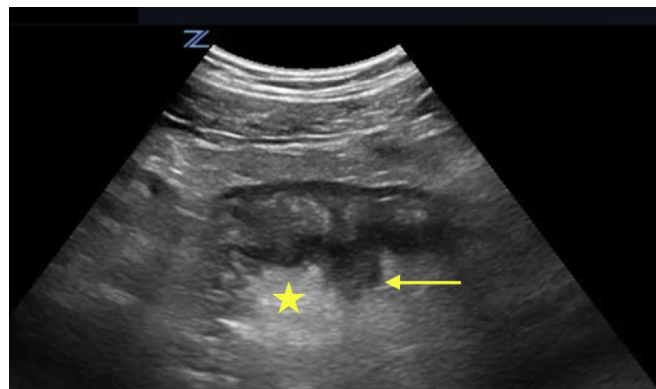


Figure 1. Diverticulitis on ultrasonography. The arrow indicates a diverticulum with associated bowel wall edema. The star indicates pericolonic infiltration observed as hyperechoic fat.

inflammatory changes), and sonographic tenderness to palpation. All 3 findings on the same location were required to make the diagnosis and can be seen in Figure 1. The scan was interpreted as having a negative result if only 1 or 2 findings were present. The thickness of the bowel wall was measured from outer wall to inner wall. Because normal bowel wall is usually less than 3 mm, a measurement of 5 mm would be considered pathologic.¹⁹ Previous studies have suggested that 4 mm is pathologic, but to improve specificity, a measurement of 5 mm was required. Sonographers recorded the ultrasonographic findings on a standard data collection form in real time.

The point-of-care ultrasonographic images were recorded as video clips and still images were saved with measurements of the bowel wall. All images were stored on a secure server. Both video clips and still images were saved for review. After completing the ultrasonographic protocol, the sonographers documented their findings on the provided data sheets and indicated whether the study result was positive or negative for acute diverticulitis, which was used for analysis. All saved images and videos were reviewed by ultrasonographic fellows and ultrasonographic fellowship-trained faculty members weekly for educational purposes; findings from these educational review sessions did not influence the sonographers' initial interpretation. Additional information collected from the medical record included the patient's demographic information, previous abdominal surgeries, history of episodes of diverticulitis, height, weight, and disposition. Data were collected by study personnel, which consisted of research associates and members of the ultrasonographic division who were specifically trained by the principal investigator (AC) to abstract data for this study. All research associates received previous training in the electronic medical record and data

abstraction, and are employed by the ED. Because the medical record data abstractions were completed with a standardized data collection form and none of the variables abstracted required clinical interpretation, dual data abstraction or interrater reliability assessment was not performed.

CT scans were performed on all patients included in this analysis. The use of contrast was ordered at the discretion of the treating physician. The final interpretation of the CT scan, dictated by a radiology attending physician, was also recorded. A CT scan result was considered positive for diverticulitis if it was listed in the impression section of the report. If acute diverticulitis was not listed there, the scan result was considered negative for diverticulitis. CT scan results were either positive or negative for diverticulitis; there were no indeterminates. CT scan results were abstracted later by study personnel who were blinded to the study results. Ultrasonographic and CT results were available for all patients who received a CT scan and point-of-care ultrasonographic examination; we did not have patients with missing test results. All data were entered into a Research Electronic Data Capture database.

Outcome Measures

The primary outcome measures of this study were the sensitivity, specificity, positive predictive value, and negative predictive value of point-of-care ultrasonography in diagnosing diverticulitis, using CT as the criterion standard for comparison.

Primary Data Analysis

We used descriptive statistics to describe the study sample. With the exception of time to complete the point-of-care ultrasonographic examination, all continuous variables were nonnormally distributed, and thus medians and interquartile ranges were reported. Frequencies and proportions were reported for categorical variables. Using CT scan results as the criterion standard for comparison, we calculated the sensitivity, specificity, positive predictive value, and negative predictive value, along with their corresponding 95% confidence intervals (CIs), of point-of-care ultrasonography in the diagnosis of diverticulitis. Before starting this study, we assumed that the sensitivity and specificity of point-of-care ultrasonography in the diagnosis of diverticulitis would both be 95%. According to previous administrative data from our ED, we expected that the prevalence of diverticulitis in our study sample would be 18%. Using a CI width of 5% and α error rate of 5%, we estimated that a sample size of 406 patients would be required to have 80% power. To account for missing

data and withdrawals, we aimed to oversample by 15% and enroll 467 patients. However, because of the low incidence of missing data and withdrawals, we stopped enrollment at 452 patients, which provided us with more than enough patients to assess our study outcomes. All statistical analyses were conducted with SAS (version 9.4; SAS Institute, Inc., Cary, NC). This study did not meet the definition of an applicable clinical trial, and thus registration with [ClinicalTrials.gov](https://www.clinicaltrials.gov) was not required.

RESULTS

A total of 462 patients met eligibility criteria for this study and were approached by a study investigator for enrollment; 1 patient refused participation and 461 provided consent (Figure 2). Of the 461 patients who provided consent, 9 were excluded from the analysis, as described in Figure 2. The final analytic sample was composed of 452 patients who received both a point-of-care ultrasonographic examination and a CT scan.

Characteristics of the study sample are shown in Table 1. Median age of the study sample was 60 years, 54% were women, 69% were white, median body mass index was 27.4 kg/m², and the majority of patients had left lower quadrant pain (67%). The most common CT scan findings were diverticulitis (36%), no acute pathology (34%), and colitis (10%). Overall, 26% of the study sample patients were admitted. Thirty-six percent of the patients with diverticulitis were admitted to the hospital.

Test characteristics of point-of-care ultrasonography in diagnosing diverticulitis compared with the criterion standard of CT scan are shown in Table 2, including sensitivity, specificity, positive predictive value, negative predictive value, and positive and negative likelihood ratios. In accordance with CT results, 161 of the 452 patients had diverticulitis (36%) and 35 (22%) received a diagnosis of complicated diverticulitis, which is defined as diverticulitis with associated abscess, phlegmon, fistula, or obstruction.²⁰

According to point-of-care ultrasonography, 158 of the 452 patients had diverticulitis (35%). This is associated with 13 false-negative (3%) and 10 false-positive (2%) point-of-care ultrasonographic examination results. A total of 164 patients were found to have diverticulosis on ultrasonography. Overall, compared with CT, point-of-care ultrasonography had a sensitivity of 92% (95% CI 88% to 96%), specificity of 97% (95% CI 94% to 99%), positive predictive value of 94% (95% CI 90% to 97%), and negative predictive value of 96% (95% CI 93% to 98%) in the diagnosis of diverticulitis. This is associated with positive and negative likelihood ratios of 30.67 and 0.08,

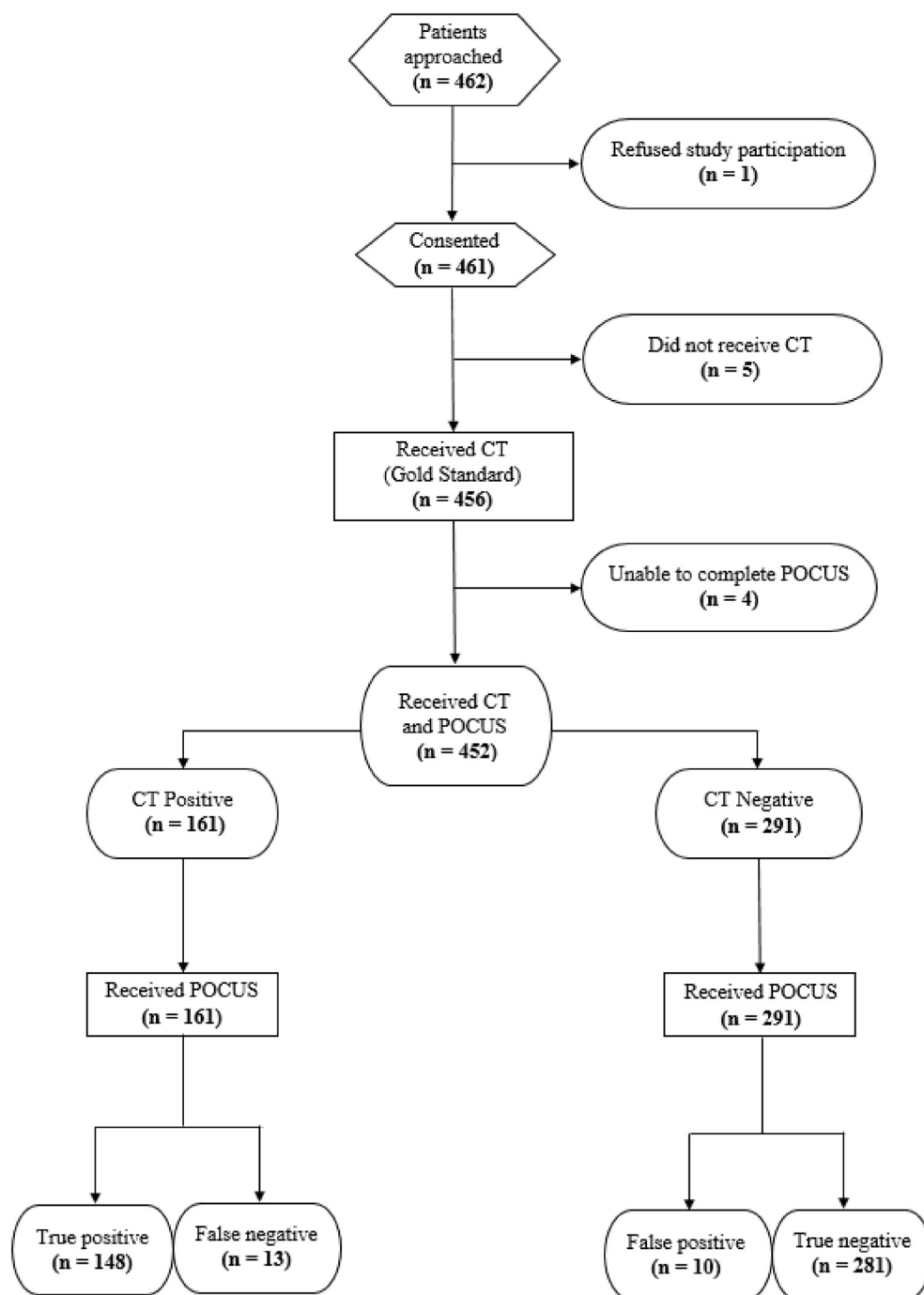


Figure 2. Subject enrollment.

respectively. The mean time to complete the point-of-care ultrasonographic examination was 4.9 minutes (SD 1.9 minutes).

LIMITATIONS

This study has several limitations. First, we enrolled patients at a single, large, academic, quaternary medical

center ED. Enrolling sonographers were highly trained in bedside point-of-care ultrasonography, which could limit the generalizability to other EDs. Small community hospital EDs may not have access to physicians who are able to obtain the images required to make the diagnosis. Further studies are needed to determine the degree of training necessary to obtain the required images and whether evaluations of clinicians without advanced

ultrasonographic training would have the same level of sensitivity and specificity as that of sonographers in our study.

Second, we enrolled a convenience sample of subjects according to availability of trained sonographers. Sonographers were mostly present weekdays from 9 AM to 5 PM; however, if enrollers were available at alternative times, then the patient could be enrolled. It is possible that some patients were not enrolled because of sonographer availability.

Third, the ultrasonographic examinations were performed by 19 ultrasonographic fellowship-trained emergency faculty and emergency ultrasonographic fellows. Although all images were recorded and saved, we did not explicitly keep track of the number of point-of-care ultrasonographic examinations performed by sonographers, and thus we are unable to report on the test performance of each sonographer in regard to true-positive, true-negative, false-positive, and false-negative rates. Through further data extrapolation and review, it was deduced that the majority of scans were performed by 5 highly trained ultrasonographic faculty members, each performing numerous scans. The sonographers' experience and expertise may have influenced the results of this investigation.

Fourth, on unique occasions, evidence of other pathology was visualized on the point-of-care ultrasonographic examination. When evaluating the abdomen, the sonographer could potentially identify pathology that could bias their interpretation. For instance, if the sonographer visualized a dilated appendix while evaluating the abdomen, this would inherently make it less likely that the cause of the patient's pain was due to diverticulitis and could therefore bias the interpretation of the images.

Fifth, a mandatory criterion for making the sonographic diagnosis of acute diverticulitis was the presence of sonographic tenderness to palpation. Because some of these patients received intravenous pain medication before study enrollment, the patient's pain response to sonographic palpation could have been masked and therefore the sensitivity of the ultrasonographic examination could have been decreased. Additionally, altered pain perception has been described in the elderly population relating to intra-abdominal processes, and further testing will be needed to determine the reliability of sonographic tenderness to palpation in acute diverticulitis.^{15,16,21,22}

Sixth, there was no assessment of interrater reliability of the research associates who assisted with medical record data abstraction. We also did not perform dual data abstraction. Although all variables abstracted by the research associates did not require clinical interpretation and were entered into a standardized data collection tool, the possibility of inaccurate data abstraction exists.

Seventh, patients were eligible for enrollment only if there was a clinical suspicion for acute diverticulitis. There is a degree of selection bias present in this study because a higher proportion of patients with diverticulitis were enrolled than initially predicted. Even though sonographers were blinded to the patients' ultimate diagnosis, there is some inherent bias because patients could be enrolled only if there was clinical suspicion for the diagnosis in question. However, in clinical practice diagnostic imaging is ordered only when there is clinical suspicion for pathology.

DISCUSSION

Abdominal pain caused by acute diverticulitis is a common ED presentation. In the ED, abdominal CT scans are frequently used to evaluate patients with suspected diverticulitis because of their high sensitivity and specificity.²³ Even though it has been shown to be an accurate imaging modality, there are limitations of CT scans, including increased cost, prolonged length of stay in the ED, increased time to diagnosis, and, most important, exposure to ionizing radiation.²⁴ In contrast, ultrasonography is noninvasive, is nonradiating, and can be performed rapidly at the patient's bedside, making it a useful imaging modality.

Although some studies have confirmed the high sensitivity and specificity of ultrasonography in the diagnosis of diverticulitis, there is a lack of large-scale studies in the ED setting, where resources, space, and time are limited. Previous reports have evaluated the potential role of ultrasonography in diagnosing diverticular disease. Smaller studies have provided evidence that ultrasonography is a valuable imaging modality for diverticulitis, showing accuracy similar to that of CT.^{13,25-27} A meta-analysis by Laméris et al¹⁴ did not show any significant difference in the accuracy between ultrasonography and CT in diagnosing diverticulitis. The results of their study, which was a meta-analysis of more than 600 patients, showed a sensitivity of 92% for ultrasonography, with a sensitivity of 94% for CT scan in detecting diverticulitis.¹⁴ These findings are similar to results of our study. There have also been smaller case studies describing the emergency physician's ability to diagnose acute diverticulitis with point-of-care ultrasonography, including a case series by Abboud et al²⁸ that focused on the use point-of-care ultrasonography to diagnose 2 cases of uncomplicated diverticulitis in the ED. The majority of previous studies have shown sensitivities of ultrasonography for detection of diverticulitis ranging from 77% to 94%.^{11,29,30}

Table 1. Sample characteristics (n=452).

Characteristic	Patients
Age, y	
Median (IQR)	60 (49–71)
Sex	
Men	210 (46.46)
Women	242 (53.54)
Race	
White	314 (69.47)
Black	39 (8.63)
Asian	24 (5.31)
Other/multiracial	73 (16.15)
Native American	2 (0.44)
Body mass index, kg/m²	
Median (IQR)	27.4 (24.5–31.4)
Temperature, °C/°F	
Median (IQR)	36.8 (36.6–37.1)/ 98.2 (97.9–98.8)
History of diverticulitis	
Yes	153 (33.85)
No	299 (66.15)
History of abdominal surgery	
Yes	175 (38.72)
No	277 (61.28)
Location of pain	
Left lower quadrant	305 (67.48)
Left upper quadrant	8 (1.77)
Right lower quadrant	35 (7.74)
Suprapubic	12 (2.65)
Diffuse	92 (20.35)
CT results	
Appendicitis	8 (1.77)
Biliary disease	9 (1.99)
Bowel obstruction	7 (1.55)
Colitis	45 (9.96)
Diverticulitis	161 (35.62)
Enteritis	7 (1.55)
Epiplonic appendagitis	12 (2.65)
Gastroenteritis	1 (0.22)
Gynecologic	6 (1.33)
Hernia	1 (0.22)
Kidney stone	36 (7.96)
No acute pathology	152 (33.63)
Other	7 (1.55)

Although there have been previous reports evaluating the utility of ultrasonography for diagnosing diverticulitis, there is a paucity of large-scale ED-centered research evaluating its diagnostic utility. To our knowledge, this is

Table 1. Continued.

Characteristic	Patients
Admission	
Yes	119 (26.33)
No	333 (73.67)
Complicated diverticulitis (n=161)	
Yes	35 (21.74)
No	126 (78.26)

IQR, Interquartile range.

Data are presented as No. (%) unless otherwise indicated.

the first large-scale prospective study performed by emergency physicians on ED patients. In this study, greater than 450 ED patients were enrolled. We found that the sensitivity and specificity of point-of-care ultrasonography in the diagnosis of diverticulitis was 92% and 97%, respectively, compared with CT. This study demonstrates that point-of-care ultrasonography can be used as an imaging modality for patients with suspected acute diverticulitis. Many patients with diverticular disease will have several episodes of diverticulitis throughout their life and therefore will likely receive multiple CT scans. Ultrasonography may have a role in the diagnostic evaluation of younger patients with suspected diverticulitis. With limited additional training, emergency physicians with advanced ultrasonographic experience can reliably identify diverticulitis with point-of-care ultrasonography.

There were 10 false-positive point-of-care ultrasonographic examination results in our study sample. When we reviewed these cases, the majority, 7 of 10, were patients with CT-confirmed colitis with coexisting noncontributory diverticulosis. This is a limitation of point-of-care ultrasonography because it is challenging to differentiate colitis from diverticulitis; however, the treatment is often the same for both pathologies. One of the false-positive results was read during final review as a negative-result study; however, the initial sonographer's interpretation remained for analysis. In this study, there were 13 false-negative point-of-care ultrasonographic examination results. These 13 cases were reviewed, and all of these patients received a diagnosis of mild diverticulitis and did not require operative intervention. Two of the false-negative results were for patients with large body mass indexes. Making the diagnosis depends on the operator's ability to visualize the bowel, and increased abdominal soft tissue can make the examination more challenging. In one patient, there was evidence of bowel wall thickening surrounding an acute diverticulum, with enhancement of the surrounding fat; however, there was no sonographic

Table 2. Test characteristics of ultrasonography in diagnosing diverticulitis (n=452).

		CT Diagnosis (n=452)		Sensitivity (95% CI)	Specificity (95% CI)	PPV (95% CI)	NPV (95% CI)
		Positive (n=161)	Negative (n=291)				
Ultrasonographic Diagnosis (n=452)	Positive (n=158)	148	10	0.92 (0.88–0.96)	0.97 (0.94–0.99)	0.94 (0.90–0.97)	0.96 (0.93–0.98)
	Negative (n=294)	13	281				

PPV, Positive predictive value; NPV, negative predictive value.
Positive likelihood ratio was 30.67. Negative likelihood ratio was 0.08.

tenderness to palpation, and therefore the point-of-care ultrasonographic examination result was deemed negative. A future study could explore the sensitivity, positive predictive value, and negative predictive value of sonographic tenderness. In this study, the bowel wall thickening was defined as greater than 5 mm, which is slightly larger than the previously cited standard of 4 mm. A larger thickness was chosen to improve the specificity of the ultrasonography. However, this contributed to a decrease in the sensitivity of the examination. Three of the 13 studies with false-negative results had all of the sonographic criteria for acute diverticulitis except that the bowel wall thickness was less than 5 mm but greater than 4 mm. Further analysis would be needed to determine what the ideal bowel wall thickness measurement should be to optimize sensitivity and specificity. Finally, one study marked as having negative results was determined to be positive for acute diverticulitis. On review of the data sheet, the sonographer did not identify the diverticulum and therefore marked the study as having negative results.

In this study, most of the patients who received a diagnosis of uncomplicated diverticulitis were discharged home and received oral antibiotics. The majority of these patients did not have significant leukocytosis on blood testing, and no identifiable abscess, free fluid, or free air was observed on ultrasonography or later confirmed on CT. Currently, management of uncomplicated diverticulitis does not require hospital admission. A previous study by Etzioni et al³¹ demonstrated that outpatient management was effective for the majority of patients with acute uncomplicated diverticulitis. Additionally, a systematic review by Jackson and Hammond³² concluded that an outpatient approach for uncomplicated diverticulitis was a reasonable treatment course. The results of this study show that ED physicians and physician assistants with advanced ultrasonographic experience can diagnose diverticulitis with point-of-care ultrasonography. Because most patients with uncomplicated diverticulitis can be managed as outpatients, the ability for rapid diagnosis could reduce ED length of

stay, as well as decrease patient exposure to ionizing radiation. In this study, 163 patients received a diagnosis of acute diverticulitis; 37 of these 163 patients received a diagnosis of complicated diverticulitis, which included the presence of an abscess, perforation, or microperforations. All of these patients had ultrasonographic signs of acute diverticulitis, as well as other sonographic findings, including the presence of free fluid, evidence of an abscess, or multiple areas of bowel wall edema surrounding a diverticulum. To our knowledge, our study is the first large one evaluating the utility of point-of-care ultrasonography in diagnosing acute diverticulitis in the ED setting; as such, the diagnostic criteria used were based on previously reported sonographic features. Further studies could evaluate the reliability of each criterion independently to determine which findings are most diagnostic of diverticulitis.

Median body mass index of our study sample was 27.4 kg/m². Because body mass index and body habitus may affect the ability of ultrasonography to visualize the bowel, the ability of point-of-care ultrasonography to diagnose diverticulitis may be different for a patient population with higher body mass index. Future studies may wish to enroll patients with a higher body mass index to evaluate its influence on test characteristics of point-of-care ultrasonography in diagnosing diverticulitis.

In conclusion, we found that point-of-care ultrasonography performed by ultrasonographic fellowship-trained emergency physicians, physician assistants, and ultrasonographic fellows had high sensitivity and specificity for diagnosing acute diverticulitis in ED patients with abdominal pain. The presence of all 3 point-of-care ultrasonographic findings, which include bowel wall edema greater than 5 mm and surrounding an adjacent diverticulum, with enhancement of the surrounding pericolonic fat, as well as sonographic tenderness to palpation, is a reliable indicator of acute diverticulitis, with a sensitivity of 92% and a specificity of 97%.

Supervising editor: Allan B. Wolfson, MD. Specific detailed information about possible conflict of interest for individual editors is available at <https://www.annemergmed.com/editors>.

Author affiliations: From the Department of Emergency Medicine, North Shore University Hospital, Manhasset, NY (Cohen, Stankard); and the Department of Emergency Medicine, Donald and Barbara Zucker School of Medicine at Hofstra/Northwell, Manhasset, NY (Li, Nelson).

Author contributions: AC conceived the study. AC and MN supervised the conduct of the study and data collection. AC, BS, and MN participated in the recruitment of patients. AC and TL managed the data, including quality control. TL provided statistical advice, provided advice on study design and methodology, and analyzed the data. AC and TL drafted the article and all authors contributed substantially to its revision. AC takes responsibility for the paper as a whole.

All authors attest to meeting the four [ICMJE.org](http://www.icmje.org) authorship criteria: (1) Substantial contributions to the conception or design of the work; or the acquisition, analysis, or interpretation of data for the work; AND (2) Drafting the work or revising it critically for important intellectual content; AND (3) Final approval of the version to be published; AND (4) Agreement to be accountable for all aspects of the work in ensuring that questions related to the accuracy or integrity of any part of the work are appropriately investigated and resolved.

Funding and support: By *Annals* policy, all authors are required to disclose any and all commercial, financial, and other relationships in any way related to the subject of this article as per ICMJE conflict of interest guidelines (see www.icmje.org). The authors have stated that no such relationships exist.

Publication dates: Received for publication January 17, 2020. Revisions received March 13, 2020; and May 4, 2020. Accepted for publication May 11, 2020.

Presented at the Society for Academic Emergency Medicine annual meeting, May 2019, Las Vegas, NV.

REFERENCES

1. Stoker J, van Randen A, Laméris W, et al. Imaging patients with acute abdominal pain. *Radiology*. 2009;253:31-46.
2. Jacobs DO. Clinical practice. Diverticulitis. *N Engl J Med*. 2007;357:2057-2066.
3. Stollman N, Raskin JB. Diverticular disease of the colon. *Lancet*. 2004;363:631-639.
4. Mazzei MA, Cioffi Squitieri N, Guerrini S, et al. Sigmoid diverticulitis: US findings. *Crit Ultrasound J*. 2013;5(suppl 1); S5-S5.
5. Ferzoco LB, Raptopoulos V, Silen W. Acute diverticulitis. *N Engl J Med*. 1998;338:1521-1526.
6. Helou N, Abdalkader M, Abu-Rustum RS. Sonography: first-line modality in the diagnosis of acute colonic diverticulitis? *J Ultrasound Med*. 2013;32:1689-1694.
7. Laurell H, Hansson LE, Gunnarsson U. Acute diverticulitis—clinical presentation and differential diagnostics. *Colorectal Dis*. 2007;9:496-502.
8. Sai VF, Velayos F, Neuhaus J, et al. Colonoscopy after CT diagnosis of diverticulitis to exclude colon cancer: a systematic literature review. *Radiology*. 2012;263:383-390.
9. Galgano SJ, McNamara MM, Peterson C, et al. Expert Panel on Gastrointestinal I. American College of Radiology Appropriateness Criteria. Left lower quadrant pain-suspected diverticulitis. *J Am Coll Radiol*. 2019;16:S141-S149.
10. Boniface KS, King JB, LeSaux MA, et al. Diagnostic accuracy and time-saving effects of point-of-care ultrasonography in patients with small bowel obstruction: a prospective study. *Ann Emerg Med*. 2019;75:246-256.
11. American College of Emergency Physicians. Ultrasound guidelines: emergency, point-of-care, and clinical ultrasound guidelines in medicine. Available at: <https://www.acep.org/patient-care/policy-statements/ultrasound-guidelines-emergency-point-of-care-and-clinical-ultrasound-guidelines-in-medicine/>. Accessed March 14, 2019.
12. Durham B, Lane B, Burbridge L, et al. Pelvic ultrasound performed by emergency physicians for the detection of ectopic pregnancy in complicated first-trimester pregnancies. *Ann Emerg Med*. 1997;29:338-347.
13. Ripollés T, Agramunt M, Martínez MJ, et al. The role of ultrasound in the diagnosis, management and evolutive prognosis of acute left-sided colonic diverticulitis: a review of 208 patients. *Eur Radiol*. 2003;13:2587-2595.
14. Laméris W, van Randen A, Bipat S, et al. Graded compression ultrasonography and computed tomography in acute colonic diverticulitis: meta-analysis of test accuracy. *Eur Radiol*. 2008;18:2498-2511.
15. Pradel JA, Adell JF, Taourel P, et al. Acute colonic diverticulitis: prospective comparative evaluation with US and CT. *Radiology*. 1997;205:503-512.
16. Schwerk WB, Schwarz S, Rothmund M. Sonography in acute colonic diverticulitis. A prospective study. *Dis Colon Rectum*. 1992;35:1077-1184.
17. Gritzmann N. (2012). Acute Colonic Diverticulitis and Diverticulosis. In: Manconi G., and Bianchi Porro G. (eds). *Ultrasound of the Gastrointestinal Tract. Medical Radiology*. Springer, Berlin, Heidelberg.
18. Mallin M, Dawson M. *Introduction to Bedside Ultrasound*. Vol 2. Lexington, KY: Emergency Ultrasound Solutions; 2012.
19. Fleischer AC, Muhletaler CA, James AE Jr. Sonographic assessment of the bowel wall. *AJR Am J Roentgenol*. 1981;136:887-891.
20. Stollman N, Smalley W, Hirano I; AGA Institute Clinical Guidelines Committee. American Gastroenterological Association institute guideline on the management of acute diverticulitis. *Gastroenterology*. 2015;149:1944-1949.
21. Cooper GS, Schlaes DM, Salata RA. Intraabdominal infection: differences in presentation and outcome between younger patients and the elderly. *Clin Infect Dis*. 1994;19:146-148.
22. Clinch D, Banerjee AK, Ostick G. Absence of abdominal pain in elderly patients with peptic ulcer. *Age Ageing*. 1984;13:120-123.
23. Tack D, Bohy P, Perlot I, et al. Suspected acute colon diverticulitis: imaging with low-dose unenhanced multi-detector row CT. *Radiology*. 2005;237:189-196.
24. Brenner DJ, Hall EJ. Computed tomography—an increasing source of radiation exposure. *N Engl J Med*. 2007;357:2277-2284.
25. Ambrosetti P, Grossholz M, Becker C, et al. Computed tomography in acute left colonic diverticulitis. *Br J Surg*. 1997;84:532-534.
26. Hollerweger A, Macheiner P, Rettenbacher T, et al. Colonic diverticulitis: diagnostic value and appearance of inflamed diverticula—sonographic evaluation. *Eur Radiol*. 2001;11:1956-1963.
27. Wilson SR, Toi A. The value of sonography in the diagnosis of acute diverticulitis of the colon. *AJR Am J Roentgenol*. 1990;154:1199-1202.
28. Abboud ME, Frasure SE, Stone MB. Ultrasound diagnosis of diverticulitis. *World J Emerg Med*. 2016;7:74-76.
29. Moll R, Mittelkötter U, Reith HB, et al. Which imaging in case of sigmoid diverticulitis? the value of ultrasound (conventional B-mode in combination with hydrocolon sonography and colour flow Doppler) in comparison to the well-established modalities like contrast

- enema and helical computer tomography. *Zentralbl Chir.* 2002;127:297-301.
30. Parente F, Greco S, Molteni M, et al. Role of early ultrasound in detecting inflammatory intestinal disorders and identifying their anatomical location within the bowel. *Aliment Pharmacol Ther.* 2003;18:1009-1016.
31. Etzioni DA, Chiu VY, Cannom RR, et al. Outpatient treatment of acute diverticulitis: rates and predictors of failure. *Dis Colon Rectum.* 2010;53:861-865.
32. Jackson JD, Hammond T. Systematic review: outpatient management of acute uncomplicated diverticulitis. *Int J Colorectal Dis.* 2014;29:775-781.