




ELSEVIER

Contents lists available at [ScienceDirect](#)

Best Practice & Research Clinical Anaesthesiology

journal homepage: www.elsevier.com/locate/bean



6

Thoracic wall blocks: From paravertebral to retrolaminar to serratus to erector spinae and back again – A review of evidence



Ki Jinn Chin, MBBS (Hons), FRCPC, Associate Professor *

Department of Anesthesia, Toronto Western Hospital, University of Toronto, 399 Bathurst Street, McL 2-405, Toronto, Ontario, M5T 2S8, Canada

Keywords:

nerve block
thoracic wall
pain management
analgesia
anesthetics
local

A multitude of thoracic wall blocks have been described, including parasternal-intercostal plane, Pecs I and II, serratus anterior plane, paraspinal-intercostal plane, erector spinae plane blocks, and retrolaminar blocks. They are almost all fascial plane blocks, relying on passive spread of local anesthetic to target nerves within the plane or in adjacent tissue compartments. They have emerged as attractive alternatives to thoracic paravertebral and epidural blocks because of their relative simplicity and safety. Although research into these techniques is still at an early stage, the available evidence indicates that they are effective in reducing opioid requirements and improving the pain experience in a wide range of clinical settings. They are best employed as part of multimodal analgesia with other systemic analgesics, rather than as sole anesthetic techniques. Catheters may be beneficial in situations where moderate-to-severe pain is expected for >12 h, although the optimal dosing regimen requires further investigation.

© 2019 Elsevier Ltd. All rights reserved.

Introduction

Before ultrasound-guided regional anesthesia, the range of thoracic wall blocks was mainly confined to three techniques: thoracic epidural analgesia (TEA), thoracic paravertebral blockade (TPVB), and intercostal nerve blocks. Ultrasound revolutionized regional anesthesia by allowing real-

* Fax: +1 416 603 6494.
E-mail address: gasgenie@gmail.com.

time visualization of anatomical structures, needle advancement, and LA spread. This led not only to refinement of existing techniques but also to the introduction of new ones. In particular, ultrasound has been critical in the development of fascial plane blocks, in which a local anesthetic (LA) is injected into a tissue plane rather than directly around nerves. These blocks are believed to work by passive spread of LA to nerves traveling within that tissue plane or to adjacent tissue compartments containing nerves. Consequently, we now have a veritable cornucopia of thoracic wall blocks to choose from (Fig. 1). The popularity of these blocks has been driven by their relative simplicity and safety, especially compared to TEA and TPVB, as well as their apparent efficacy. The objective of this review is to provide an overview of these techniques and to summarize the currently available evidence for their use in the management of acute pain.

Techniques

As illustrated in Fig. 1, thoracic wall blocks can be performed at various points of injection along the thorax, from anterior to lateral to posterior. A brief description of the described techniques follows. It should be noted that several names may exist in the literature for what is essentially the same technique targeting the same tissue plane, with only subtle differences in probe placement or needle trajectory.

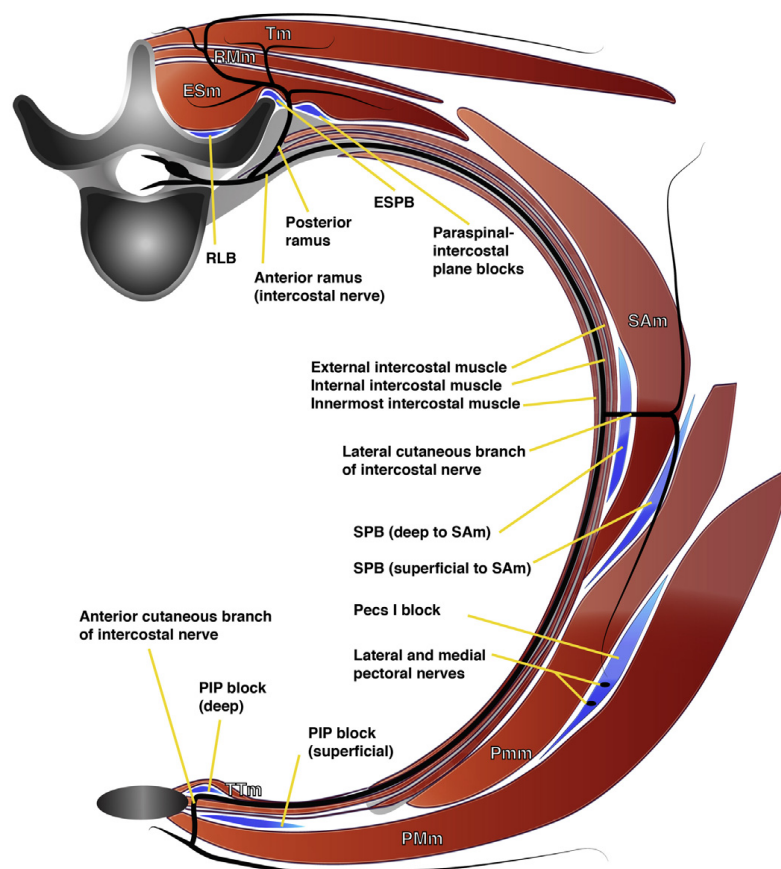


Fig. 1. Thoracic wall fascial plane blocks may be performed in various locations along the thoracic wall. The anteromedial group includes the superficial and deep parasternal-intercostal plane (PIP) blocks. The anterolateral group includes the pectoralis type 1 (Pecs I), superficial and deep serratus anterior plane block (SPB), and the Pecs II block (a combination of both Pecs I and superficial serratus anterior plane block). The posterolateral group includes the paraspinal-intercostal plane blocks, the erector spinae plane block (ESPB), and retrolaminar block (RLB). Tm (trapezius muscle), RMm (rhomboid major muscle), ESm (erector spinae muscle), SAM (serratus anterior muscle), Pmm (pectoralis minor muscle), PMm (pectoralis major muscle), and TTm (transversus thoracis muscle). (Image reproduced with permission from Dr Kim Wild)

Anterolateral chest wall blocks

The serratus anterior plane (SAP) block [1], pectoral block type 1 (Pecs I) [2], and pectoral block type 2 (Pecs II) [3] were first introduced as safer alternatives to TPVB for breast surgery. It is important to note that the Pecs I and SAP blocks are distinct techniques that target two different fascial planes, whereas the Pecs II involves injection into both of these fascial planes and is therefore a combination of both Pecs I block and SAP block.

Serratus anterior plane (SAP) block

The basic SAP block involves LA injection into a fascial plane that may be either superficial to or deep into the serratus anterior muscle, i.e., either between serratus anterior muscle and pectoralis minor or latissimus dorsi muscles, or between serratus anterior muscle and intercostal muscles and ribs. The SAP block may be performed anywhere in an area bounded by the anterior axillary line and posterior axillary line, and the second to seventh ribs. Both superficial and deep SAP blocks primarily target the lateral cutaneous branches of intercostal nerves [4–6], with the actual nerves involved being determined largely by the exact point of injection and the volume of injectate [6]. However, the efficacy of the SAP block in thoracotomy and rib fractures [7,8] suggests that it may also anesthetize deeper structures, although cadaveric studies have yet to demonstrate this. The long thoracic nerve and thoracodorsal nerve also run in the superficial serratus anterior muscle plane and may therefore be inadvertently or deliberately anesthetized by a superficial SAP block [5,9]. It is presently unclear whether there are significant differences in analgesic efficacy between the superficial and deep SAP blocks [10,11].

Pectoral block type I (Pecs I)

The Pecs I block involves LA injection into the fascial plane between pectoralis minor and major muscles. The usual point of injection is where the pectoral branch of the thoracoacromial artery enters the interpectoral plane, accompanied by the lateral pectoral nerve [2,12,13]. Branches of the medial pectoral nerve (which lies deep into pectoralis minor) enter the fascial plane inferolateral to this point [13]. The pectoral nerves innervate only the pectoral muscles and not the overlying cutaneous tissues [14] but are, nevertheless, valuable, where there is a component of pain due to stretch or surgical injury to the muscles.

Pectoral block type II (Pecs II)

The defining characteristic of the Pecs II block technique is two separate injections of LA: the first between the pectoralis minor and major muscles (i.e., Pecs I block, usually with 10 ml in adults), and the second superficial to the serratus plane muscle (i.e., SAP block, usually with 20 ml) at the level of the third to the fourth rib in the anterior axillary line. Both injections are generally accomplished with a single needle pass, although varying probe positions and needle trajectories have been described [3,15,16].

Anteromedial chest wall blocks

Parasternal-intercostal plane blocks

The anteromedial chest wall (i.e., the sternum and parasternal region) is innervated by the anterior branches of the intercostal nerves. The Pecs II and SAP blocks, which primarily anesthetize the lateral cutaneous branches, are not expected to reliably cover this area, although a recent study of Pecs II block in median sternotomy calls this into question [17]. These terminal anterior branches ascend in the parasternal region through the intercostal and pectoralis major muscles to innervate the superficial tissues. They can thus be targeted in one of two fascial planes: either deep into intercostal muscles and superficial to transversus thoracis muscles or superficial to the intercostal muscles and deep into pectoralis major muscle. The transversus thoracic plane (TTP) block utilizes the first approach with an injection between the third and fourth ribs [18,19]. The second approach has been described in several reports, each using slightly different sonographic landmarks and names. These include the pecto-intercostal block [20], subpectoral interfascial plane block [21], parasternal intercostal nerve block [22], and the anterior thoracic medial block [23]. As with the SAP block, it may be more rational to describe these techniques as either deep or superficial parasternal-intercostal plane blocks, based on the anatomical location that is targeted [62].

Posterolateral chest wall blocks

Paraspinal-intercostal plane blocks

The fascial plane superficial to the intercostal muscles and ribs (the target of the deep SAP block) extends posteriorly to the spinal midline, varying only with regard to the identity of the overlying muscle layer (Fig. 1). Depending on the area in question, this may be the rhomboid or erector spinae (iliocostalis and longissimus thoracis) muscles. Several approaches have been described, which this review will refer to collectively as paraspinal-intercostal plane blocks. The earliest of these involved tunneling a multi-orifice catheter longitudinally across multiple ribs to provide “continuous intercostal blockade” [24–26] or “posterior paramedian subrhomboidal analgesia” [27] for rib fracture analgesia. Ultrasound-guided variations of the paraspinal-intercostal plane block have also been described [28,29]. The latest iteration is the rhomboid intercostal sub-serratus (RISS) block, which hybridizes both paraspinal-intercostal plane and deep SAP blockade into one approach [30]. Cadaveric studies indicate that LA injected into the paraspinal-intercostal plane spreads primarily to lateral cutaneous branches of the ventral rami of spinal nerves with no staining of intercostal nerves themselves [28,30]. However, as with the deep SAP block, reports of efficacy in thoracic surgery [29,30] and rib fracture analgesia [25–27] suggest that there must be other mechanisms of analgesic action.

Retrolaminar block

The retrolaminar block was described in 2006 [31] as a simpler surface landmark-guided alternative to the TPVB (23,24). Rather than seeking to pierce the superior costotransverse ligament and enter the paravertebral space, the aim in the retrolaminar block is merely to contact the bony vertebral lamina. LA is injected into the fascial plane between the posterior surface of the thoracic lamina and the overlying transversospinalis muscles. In the ultrasound-guided approach to the retrolaminar block, the lamina, overlying muscle, and the LA spread between them are directly visualized [32]. Cadaveric studies have confirmed that the injectate subsequently spreads anteriorly through the intertransverse ligaments into the paravertebral and epidural spaces over 2–4 segmental levels [33,34].

Erector spinae plane (ESP) block

The ESP block is a recently described ultrasound-guided technique in which LA is injected into a fascial plane between the tips of the thoracic transverse processes and the overlying erector spinae muscle (longissimus thoracis) [35,36]. It is conceptually similar to the retrolaminar block and the paraspinal intercostal plane blocks, differing primarily in the bony landmark that is sought (transverse process versus lamina versus rib). Consistent with the anatomical middle ground it occupies, cadaveric and imaging studies indicate that the ESP block results in injectate spread not only to paravertebral and epidural spaces [33–35,37] but also to lateral cutaneous branches of the intercostal nerves [33,38]. Injectate spreads from a single point of injection to 3–5 segmental levels in the epidural space and 6–10 levels in the intercostal area [33,34,38].

Mid-point transverse process to pleura (MTP) block

The MTP block is an ultrasound-guided alternative to TPVB, in which the needle tip is inserted beyond the posterior aspect of transverse processes but remains superficial to the superior costotransverse ligament [39]. Cadaveric investigation shows that fluid injected in this location spreads anteriorly into the paravertebral space. The MTP block may therefore be as effective as TPVB while carrying less risk of pleural puncture; however, it has yet to be fully investigated [40].

Which thoracic wall block to do and when?

Thoracic wall blocks as alternatives to TEA and TPVB – which to choose?

One of the primary indications for the thoracic wall blocks described above is the alternatives to TEA and TPVB. Their chief advantages with regard to this are ease of performance and safety. There is no need to locate and traverse the thoracic interlaminar spaces or the superior costotransverse ligament,

and ultrasound can be used to guide needle insertion and confirm correct tip placement by visualization of a characteristic pattern of fluid spread. As the targets for injection are distant from critical anatomical structures, there is theoretically little to no risk of spinal cord or nerve injury, epidural hematoma or infection, major vascular injury, and pleural puncture or lung injury. The trade-off of these “indirect” blocks is that somatic and sympathetic blockade may be less consistent or intense and quality of analgesia possibly inferior [41]. This, however, has yet to be conclusively determined.

Given the paucity of head-to-head trials at this time, the choice of block to perform is influenced mainly by the desired area of coverage and technical considerations. The parasternal-intercostal blocks should cover the parasternal region; Pecs I, Pecs II, and SAP blocks should cover the axilla and anterolateral thorax; and the posterior paraspinal blocks should cover almost the entire hemithorax. The anterior wall blocks are readily performed in the supine position, whereas the paraspinal-intercostal, ESP, and retrolaminar blocks require that the patient be in a lateral, sitting, or prone position. Wound dressings and drains may limit probe placement and needle insertion, and there may be disruption of tissue planes by air, fluid, or trauma. These factors may in turn influence the timing of block performance: before or after induction of general anesthesia, pre-incision, or at the end of surgery.

Risks and complications of thoracic wall blocks

As discussed above, the anatomy of thoracic wall blocks means that they are relatively safe techniques with a minimal risk of serious needle-related complications. Hypotension is a potential concern with retrolaminar and ESP blocks, as epidural spread has been documented [33,37]. Nevertheless, it is likely that the mass of LA reaching the epidural space is too small in most cases to result in a hemodynamically significant sympathectomy [42,43].

The most important risk is that of LA systemic toxicity (LAST), as large volumes of LA are injected into well-vascularized tissues. Although there are currently no published cases of LAST after thoracic wall blocks, the risk is expected to be similar to that of abdominal wall blocks, where multiple cases have been reported [44]. The following precautions should therefore always be observed: (1) keep within the maximum recommended weight-based LA dose limits, (2) add epinephrine (e.g., 5 µg/ml), to reduce systemic absorption (even with ropivacaine [45]), (3) monitor patients for at least 30 min, and (4) ensure availability of a LAST rescue kit [46].

Thoracic wall blocks and coagulation abnormalities

The 4th edition of the American Society of Regional Anesthesia guidelines suggests that for procedures other than neuraxial, deep plexus, or deep peripheral nerve blocks, management should be governed by consideration of “site compressibility, vascularity, and consequences of bleeding” [47]. The injection site of most thoracic wall blocks is compressible because of their superficial nature and a bony “floor.” There are no major vessels in the vicinity, hence making vascular injury and significant hemorrhage highly unlikely. Hematoma at the site of injection is possible but rare. Ueshima et al. reported the complication rate in a series of 299 TTP blocks [48] and 498 Pecs II blocks [49]. There were no hematomas in the TTP group versus 8 in the Pecs II group (1.6%) for an overall incidence of 1%. More importantly, significant sequelae from the hematomas were not observed; secondary neural compression or ischemia is extremely unlikely with any of the thoracic wall blocks. Thoracic wall blocks have been used in anticoagulated patients, including full heparinization [42,43,50,51], but ultimately, any decision must be made by a careful risk–benefit analysis in the individual patient.

Expectations of efficacy – how well will thoracic wall blocks work?

Thoracic wall blocks rely on passive spread of LA, and consequently, only a proportion of the total injected mass of LA will reach and act on target nerves. The actual mass of LA and the nerves it reaches are dependent on a multitude of potential factors including volume, direction of injection, speed of injection, respiratory movement, gravity, and others yet to be elucidated. As such, there will be inevitable interindividual variation in the extent and intensity of sensory loss. This was illustrated in a recent study of the SAP block [52], in which there was a discrepancy between analgesic effect and loss

of sensation to different testing modalities. All patients had excellent early analgesia; however, loss of sensation to cold and pinprick ranged from 2 to 7 and 1 to 6 dermatomes, respectively, following injection of 20 ml of LA. Injection of a larger volume (40 ml) produced similarly variable results, with loss of sensation to cold and pinprick ranging from 3 to 8 and 1 to 8 dermatomes, respectively.

The concept of differential blockade may explain these observations and the clinical effect of thoracic wall blocks. Very low concentrations of LA applied to nerves will preferentially block unmyelinated C fibers (responsible for the majority of nociception) over the larger A-delta (which transmit fast-onset pain) and A-gamma fibers (involved in touch, proprioception, and motor function but not nociception) [53]. It is therefore conceivable that these fascial plane blocks may produce analgesia despite the absence of discernible sensory and motor block.

Two final considerations are that of contralateral innervation across the midline [54] and overlapping innervation between adjacent nerves [55]. Unilateral blocks can therefore fail to provide complete analgesia of the medial thorax. The communication that exists between nerves from the C3 and C4 roots (the supraclavicular nerves anteriorly and the spinal accessory nerve posteriorly) and branches of the T2 spinal nerve, as well as between contiguous spinal nerves [55], may be a further reason for incomplete sensory loss.

As a result, thoracic wall blocks should be regarded not as sole anesthetic techniques but rather as an additional component of multimodal analgesia that provides opioid-sparing rather than opioid-eliminating effects. The insertion of catheters is advantageous in allowing infusion or repeated boluses of LA, which will prolong and may even augment the analgesic effect [8,42,56,57].

Efficacy in breast surgery

Pecs II block is currently the most widely studied thoracic wall block in breast surgery, with a recent meta-analysis [58] identifying 8 studies (572 patients) that compare it to systemic analgesia and 5 studies (243 patients) that compare it to TPVB. Compared to systemic analgesia alone, Pecs II block reduced 24-h opioid requirements (by 13.6 mg of oral morphine), prolonged time to first analgesic request (by 301 min) and reduced 24-h pain scores by 0.9–1.9 points on average [58]. There was no significant difference between the Pecs II block and TPVB in any of these measures. No complications of the Pecs II block were reported in any of the included studies. The benefits of the Pecs II block may be greater if combined with other regional anesthetic techniques. O'Scanaill et al. demonstrated that a combination of pre-incisional Pecs II block and postoperative continuous wound infiltration provides analgesia superior to that by either technique alone [59]. In particular, combining Pecs II block with TPVB may be the optimal method for conducting “general anesthesia-free” breast surgery [60,61]. Addition of a TTP block to a Pecs II block also resulted in lower pain scores and reduced analgesic requirements, presumably due to better coverage of the medial aspect of the breast [62].

Two randomized controlled trials (RCTs) have compared the superficial SAP block alone to TPVB in breast surgery. Both reported similar intraoperative opioid requirements between groups, but 24-h opioid requirements and time to first analgesic request were longer in patients who received TPVB [63,64]. A third RCT comparing a deep SAP block with TPVB reported that the SAP block was easier to perform, and the postoperative quality of recovery was similar in both groups [65].

It should be noted that there are surgical caveats to the superficial SAP and Pecs II block in breast surgery: the injectate may hinder axillary nodal dissection and blockade of the long thoracic nerve and thoracodorsal nerve prevents electrolocation and surgical preservation of these nerves. One alternative is to perform only a Pecs I block, although there is conflicting evidence for this. Preincisional Pecs I block did not reduce pain scores or opioid consumption when added to a regimen of LA wound infiltration, oral acetaminophen, and NSAID therapy, except in the small subgroup undergoing major surgery and then only during the early postoperative period [66]. A Pecs 1 catheter was also found to be less effective than a superficial SAP catheter following modified radical mastectomy [67]. A retrospective review, on the other hand, reported a reduction in opioid use (mean of 20 mg oral morphine) and the incidence of postoperative nausea and vomiting (32% vs. 89%) with a Pecs I block compared to no block [68]. The Pecs I block was noninferior to a deep SAP block in the same population [68].

Posterior paraspinal blocks offer the advantage of preoperative catheter insertion, which must be weighed against the patient positioning needed to perform the block. The present evidence for these techniques is limited and somewhat mixed. A small case series demonstrated that a continuous

landmark-guided retrolaminar block provided significant opioid-sparing following breast surgery [69], and this technique was later shown to provide analgesia comparable to that of continuous TPVB, albeit with higher local anesthesia dose requirements [57]. A single-injection bilevel landmark-guided retrolaminar block, however, failed to demonstrate any benefit over placebo [70]. This may reflect the importance of adequate LA and dose in achieving effective spread [71].

Numerous case reports support the efficacy of the ESP block in major breast surgery [72–75], and a recent RCT demonstrated significant reduction in postoperative opioid consumption with a single-injection ESP block compared to systemic analgesia alone [76]. On the other hand, another RCT reported that the analgesia in modified radical mastectomy is inferior with the ESP block compared to a Pecs II block [77]. Further comparative studies are awaited.

Efficacy in thoracic surgery

Thoracic wall blocks are a logical option in thoracic surgery. The side-effect profile is superior to TEA and TPVB, and patients are placed in a lateral decubitus position for surgery, facilitating block performance after induction of anesthesia, particularly the posterior paraspinal techniques. To date the SAP block is the only one that has been studied in RCTs. The evidence for other blocks is confined to case reports illustrating their efficacy where TEA or TPVB have failed or are not feasible [78–81].

Saad et al. reported that while a single-injection pre-incisional superficial SAP block provided superior analgesia following thoracotomy compared to a control group, it was not as effective as TPVB [82]. Median pain scores were higher starting 12 h after surgery, and 97% in the SAP group required supplemental opioids in the first 24 h compared to 23% in the TPVB group. However, none of the SAP group patients experienced hypotension, versus 13% of the TPVB group patients. A continuous catheter technique may improve efficacy, as shown in a study comparing continuous superficial SAP block with TEA in patients undergoing thoracotomy [8]. The SAP catheter was inserted at the end of surgery and resulted in similar pain scores, need for rescue analgesia, and 24-h opioid consumption compared to a TEA regimen utilizing the same rate of LA infusion. The SAP block again proved advantageous in maintaining hemodynamic stability, whereas in the TEA group, mean arterial pressures were consistently lower than baseline pressure and 20% of patients required active treatment for hypotension.

The role of SAP blocks in video-assisted thoracoscopic surgery is less clear. In two studies, a pre-incisional single-injection deep SAP block was compared to a multimodal postoperative analgesic regimen of opioids, acetaminophen, and NSAIDs, and although the SAP block produced statistically significant improvements in intraoperative and postoperative analgesic outcomes, these were modest and largely confined to the early postoperative period [83,84]. The SAP block, however, produced a clinically meaningful difference in the quality of recovery (QoR-40) scores on postoperative days 1 and 2 [84]. Possible reasons for the underwhelming results include the limited duration of single-injection blocks and the lack of visceral analgesia.

Efficacy in cardiac surgery

The use of TEA and TPVB in cardiac surgery is limited by the need for perioperative anticoagulation, and thoracic wall blocks are therefore an attractive alternative. Continuous ESP blockade has been used to provide effective analgesia for thoracotomy associated with LVAD implantation, demonstrating feasibility even in the presence of full heparinization [50].

Bilateral thoracic wall blocks have also been shown to provide superior analgesia following median sternotomy when added to a regimen of IV acetaminophen and tramadol. Kumar et al. performed bilateral postoperative Pecs II blocks once patients had been stabilized in the intensive care unit (ICU) and reported that patients receiving the block were extubated earlier, had lower pain scores up to 18 h after extubation, and had markedly fewer requests for rescue analgesia in the first 12 h than controls [17]. Krishna et al. performed bilateral preoperative single-injection ESP blocks and found that this reduced intraoperative fentanyl requirements, time to extubation, and pain scores and need for rescue analgesia in the first 12 h after extubation [43]. Furthermore, the superior analgesia translated into improvements in longer term outcomes: patients in the ESP block group ambulated earlier (36 h vs. 62 h post-extubation), resumed oral intake earlier (30 vs. 49 h), and had a shorter ICU length of stay (42 vs. 69 h).

A third RCT compared bilateral ESP catheters with TEA in patients undergoing median sternotomy and found no significant differences in any of the outcomes studied, including intraoperative opioid

use, time to extubation, ICU length of stay, postoperative pain scores, need for rescue analgesia, and incentive spirometry volumes [42].

Efficacy in thoracic trauma

Numerous case reports have demonstrated the efficacy of thoracic wall blocks for analgesia following thoracic trauma. Parasternal intercostal blocks have been used for sternal fractures [21]. The options in rib fractures include SAP [7,85], paraspinal intercostal [25–27], and ESP blocks [36,86], with the choice depending mainly on location of fractures, factors limiting patient positioning, and operator experience. Retrospective and nonrandomized comparative studies have demonstrated that paraspinal-intercostal block catheters result in significant improvements in resting and dynamic pain scores, inspiratory volumes, and length of hospital stay [25] and that they may be as effective as TEA [26,27]. Most recently, a retrospective cohort study of 79 patients with multiple rib fractures reported that ESP blocks significantly improved inspiratory volumes and opioid consumption, particularly when a continuous catheter technique was employed [87].

Conclusion

Thoracic wall blocks represent a significant advancement in regional anesthesia for their simplicity and safety. Our current understanding of their mechanisms of action indicates that they should not be expected to consistently provide the same degree of analgesia as a well-functioning epidural or TPVB. Nevertheless, the available evidence indicates that they are still highly effective in reducing opioid requirements and improving pain experience in a wide range of clinical settings. They are therefore best employed as part of multimodal analgesia with other systemic analgesics. Catheters may be beneficial in situations where moderate-to-severe pain is expected for >12 h, although the optimal dosing regimen requires further investigation. Research into these techniques is still at an early stage, and well-designed comparative trials are needed to ascertain the optimal choice of technique for specific surgical applications. Until then, they may be regarded as viable alternatives to the traditional techniques of TEA and TPVB, particularly where these are contraindicated or not feasible.

Conflict of interest

None.

Practice points

- Thoracic wall blocks are an option for analgesia in thoracic surgery or trauma, especially if thoracic paravertebral or epidural analgesia is not feasible.
- The decision as to which block to perform is governed by factors including desired area of coverage, the available sites for ultrasound probe placement and needle insertion, patient positioning, and operator experience.
- The extent and intensity of sensory loss can be quite variable, and the blocks should always be combined with systemic multimodal analgesia to maximize opioid-sparing.
- The effective duration of most single-injection techniques is 8–12 h, and catheter insertion should be considered if a more prolonged effect is desired. Re-dosing through a catheter can also improve the quality of analgesia.
- Thoracic wall blocks may be considered in patients with coagulation abnormalities after a careful evaluation of the potential benefit versus the risks of associated with hematoma formation or vascular injury.
- An adequate volume of local anesthetic is necessary for efficacy, as these are fascial plane blocks and rely on passive spread to target nerves. However, local anesthetic systemic toxicity is a real risk, and precautions must be observed including staying within the maximum recommended dose limits, adding epinephrine to the local anesthetic, monitoring patients, and being prepared to treat systemic toxicity if it occurs.

Research agenda

- Well-designed comparative trials are required for many of the newer thoracic wall blocks to determine their efficacy than thoracic paravertebral and epidural analgesia, as well as to each other.
- Further investigation is needed into the impact of thoracic wall blocks on patient-centered outcomes other than analgesia.
- The available evidence suggests that continuous catheter techniques may be more efficacious than single-injection blocks; however, additional comparative studies are needed.
- The optimal dosing regimen for catheters also needs to be defined with regard to local anesthetic concentration, infusion rate, and continuous infusion versus intermittent bolus dosing.
- Pharmacokinetic studies are needed to better establish the risk of local anesthetic systemic toxicity and define the upper limits of safe dosing.

References

- [1] Blanco R, Parras T, McDonnell JG, et al. Serratus plane block: a novel ultrasound-guided thoracic wall nerve block. *Anaesthesia* 2013;68:1107–13.
- [2] Blanco R. The “pecs block”: a novel technique for providing analgesia after breast surgery. *Anaesthesia* 2011;66:847–8.
- [3] Blanco R, Fajardo M, Parras Maldonado T. Ultrasound description of Pecs II (modified Pecs I): a novel approach to breast surgery. *Rev Esp Anesthesiol Reanim* 2012;59:470–5.
- [4] Mayes J, Davison E, Panahi P, et al. An anatomical evaluation of the serratus anterior plane block. *Anaesthesia* 2016;71:1064–9.
- [5] Kunigo T, Murouchi T, Yamamoto S, et al. Spread of injectate in ultrasound-guided serratus plane block: a cadaveric study. *JA Clin Rep* 2018;4:10.
- *[6] Biswas A, Castanov V, Li Z, et al. Serratus plane block: a cadaveric study to evaluate optimal injectate spread. *Reg Anesth Pain Med* 2018;43:854–8.
- [7] Durant E, Dixon B, Luftig J, et al. Ultrasound-guided serratus plane block for ED rib fracture pain control. *Am J Emerg Med* 2016;35:197.
- *[8] Khalil AE, Abdallah NM, Bashandy GM, et al. Ultrasound-guided serratus anterior plane block versus thoracic epidural analgesia for thoracotomy pain. *J Cardiothorac Vasc Anesth* 2017;31:152–8.
- [9] Ueshima H, Iwamoto W, Otake H. Serratus plane block for a contraction of the latissimus dorsi muscle. *Reg Anesth Pain Med* 2016;41:411.
- [10] Abdallah FW, Cil T, MacLean D, et al. Too deep or not too deep?: a propensity-matched comparison of the analgesic effects of a superficial versus deep serratus fascial plane block for ambulatory breast cancer surgery. *Reg Anesth Pain Med* 2018;43:480–7.
- [11] Piracha MM, Thorp SL, Puttanniah V, et al. “A tale of two planes”: deep versus superficial serratus plane block for postmastectomy pain syndrome. *Reg Anesth Pain Med* 2017;42:259–62.
- [12] Pérez MF, Miguel JG, de la Torre PA. A new approach to pectoralis block. *Anaesthesia* 2013;68:430.
- [13] Carstensen LF, Jenstrup M, Lund J, et al. Pectoral block failure may be due to incomplete coverage of anatomical targets: a dissection study. *Reg Anesth Pain Med* 2018;43:844–8.
- [14] Desroches J, Belliveau M, Bilodeau C, et al. Pectoral nerves I block is associated with a significant motor blockade with no dermatomal sensory changes: a prospective volunteer randomized-controlled double-blind study. *Can J Anaesth* 2018;65:806–12.
- [15] Desroches J, Grabs U, Grabs D. Selective ultrasound guided pectoral nerve targeting in breast augmentation: how to spare the brachial plexus cords? *Clin Anat* 2013;26:49–55.
- [16] Pérez MF, Duany O, de la Torre PA. Redefining PECS blocks for postmastectomy analgesia. *Reg Anesth Pain Med* 2015;40:729–30.
- [17] Kumar KN, Kalyane RN, Singh NG, et al. Efficacy of bilateral pectoralis nerve block for ultrafast tracking and postoperative pain management in cardiac surgery. *Ann Card Anaesth* 2018;21:333–8.
- [18] Ueshima H, Kitamura A. Blocking of multiple anterior branches of intercostal nerves (Th2-6) using a transversus thoracic muscle plane block. *Reg Anesth Pain Med* 2015;40:388.
- [19] Ueshima H, Takeda Y, Ishikawa S, et al. Ultrasound-guided transversus thoracic muscle plane block: a cadaveric study of the spread of injectate. *J Clin Anesth* 2015;27:696.
- [20] de la Torre PA, García PD, Alvarez SL, et al. A novel ultrasound-guided block: a promising alternative for breast analgesia. *Aesthet Surg J* 2014;34:198–200.
- [21] Raza I, Narayanan M, Venkataraju A, et al. Bilateral subpectoral interfascial plane catheters for analgesia for sternal fractures: a case report. *Reg Anesth Pain Med* 2016;41:607–9.
- [22] Ohgoshi Y, Ino K, Matsukawa M. Ultrasound-guided parasternal intercostal nerve block. *J Anesth* 2016;30:916.
- [23] Takahashi H, Suzuki T. Anterior thoracic medial block for administering postoperative analgesia in the internal mammary area. *Reg Anesth Pain Med* 2016;41:660–1.

- [24] Truitt MS, Mooty RC, Amos J, et al. Out with the old, in with the new: a novel approach to treating pain associated with rib fractures. *World J Surg* 2010;34:2359–62.
- [25] Truitt MS, Murry J, Amos J, et al. Continuous intercostal nerve blockade for rib fractures: ready for primetime? *J Trauma* 2011;71:1548–52.
- [26] Britt T, Sturm R, Ricardi R, et al. Comparative evaluation of continuous intercostal nerve block or epidural analgesia on the rate of respiratory complications, intensive care unit, and hospital stay following traumatic rib fractures: a retrospective review. *Local Reg Anesth* 2015;8:79–84.
- [27] Shelley CL, Berry S, Howard J, et al. Posterior paramedian subrhomboidal analgesia versus thoracic epidural analgesia for pain control in patients with multiple rib fractures. *J Trauma Acute Care Surg* 2016;81:463–7.
- [28] Bryskin RB, Robie DK, Mansfield FM, et al. Introduction of a novel ultrasound-guided extrathoracic sub-paraspinal block for control of perioperative pain in Nuss procedure patients. *J Pediatr Surg* 2017;52:484–91.
- [29] Roué C, Wallaert M, Kacha M, et al. Intercostal/paraspinal nerve block for thoracic surgery. *Anaesthesia* 2016;71:112–3.
- [30] Elsharkawy H, Maniker R, Bolash R, et al. Rhomboid intercostal and subserratus plane block: a cadaveric and clinical evaluation. *Reg Anesth Pain Med* 2018;43:745–51.
- [31] Pfeiffer G, Oppitz N, Schöne S, et al. Analgesia of the axilla using a paravertebral catheter in the lamina technique. *Anaesthesist* 2006;55:423–7.
- [32] Zeballos JL, Voscopoulos C, Kapottos M, et al. Ultrasound-guided retrolaminar paravertebral block. *Anaesthesia* 2013;68:649–51. <https://doi.org/10.1111/anae.12296>.
- *[33] Adhikary SD, Bernard S, Lopez H, et al. Erector spinae plane block versus retrolaminar block: a magnetic resonance imaging and anatomical study. *Reg Anesth Pain Med* 2018;43:756–62.
- [34] Yang H-M, Choi YJ, Kwon H-J, et al. Comparison of injectate spread and nerve involvement between retrolaminar and erector spinae plane blocks in the thoracic region: a cadaveric study. *Anaesthesia* 2018;73:1244–50.
- [35] Forero M, Adhikary SD, Lopez H, et al. The erector spinae plane block: a novel analgesic technique in thoracic neuropathic pain. *Reg Anesth Pain Med* 2016;41:621–7.
- [36] Luftig J, Mantuani D, Herring AA, et al. Successful emergency pain control for posterior rib fractures with ultrasound-guided erector spinae plane block. *Am J Emerg Med* 2018;36:1391–6.
- [37] Schwartzmann A, Peng P, Maciel MA, et al. Mechanism of the erector spinae plane block: insights from a magnetic resonance imaging study. *Can J Anaesth* 2018;65:1165–6.
- [38] Ivanusic J, Konishi Y, Barrington MJ. A cadaveric study investigating the mechanism of action of erector spinae blockade. *Reg Anesth Pain Med* 2018;43:567–71.
- [39] Costache I, de Neumann L, Ramnanan CJ, et al. The mid-point transverse process to pleura (MTP) block: a new end-point for thoracic paravertebral block. *Anaesthesia* 2017;72:1230–6.
- [40] Costache I, Abdallah FW, Pawa A. MTP block anatomy and paravertebral spread - a reply. *Anaesthesia* 2017;72:1561–2.
- [41] Costache I, Pawa A, Abdallah FW. Paravertebral by proxy - time to redefine the paravertebral block. *Anaesthesia* 2018;73:1185–8.
- *[42] Nagaraja PS, Ragavendran S, Singh NG, et al. Comparison of continuous thoracic epidural analgesia with bilateral erector spinae plane block for perioperative pain management in cardiac surgery. *Ann Card Anaesth* 2018;21:323–7.
- *[43] Krishna SN, Chauhan S, Bhoi D, et al. Bilateral erector spinae plane block for acute post-surgical pain in adult cardiac surgical patients: a randomized controlled trial. *J Cardiothorac Vasc Anesth* 2019;33:368–75.
- [44] Chin KJ, McDonnell JG, Carvalho B, et al. Essentials of our current understanding: abdominal wall blocks. *Reg Anesth Pain Med* 2017;42:133–83.
- [45] Corvetto MA, Echevarría GC, De La Fuente N, et al. Comparison of plasma concentrations of levobupivacaine with and without epinephrine for transversus abdominis plane block. *Reg Anesth Pain Med* 2012;37:633–7.
- [46] Neal JM, Barrington MJ, Fettiplace MR, et al. The third American society of regional anesthesia and pain medicine practice advisory on local anesthetic systemic toxicity: executive summary 2017. *Reg Anesth Pain Med* 2018;43:113–23.
- [47] Horlocker TT, Vandermeulen E, Kopp SL, et al. Regional anesthesia in the patient receiving antithrombotic or thrombolytic therapy: American society of regional anesthesia and pain medicine evidence-based guidelines (fourth edition). *Reg Anesth Pain Med* 2018;43:263–309.
- [48] Ueshima H, Otake H. Ultrasound-guided transversus thoracic muscle plane block: complication in 299 consecutive cases. *J Clin Anesth* 2017;41:60.
- [49] Ueshima H, Otake H. Ultrasound-guided pectoral nerves (PECS) block: complications observed in 498 consecutive cases. *J Clin Anesth* 2017;42:46.
- [50] Adhikary SD, Prasad A, Soleimani B, et al. Continuous erector spinae plane block as an effective analgesic option in anticoagulated patients after left ventricular assist device implantation: a case series. *J Cardiothorac Vasc Anesth* 2019;33:1063–7.
- [51] Leyva FM, Mendiola WE, Bonilla AJ, et al. Continuous erector spinae plane (ESP) block for postoperative analgesia after minimally invasive mitral valve surgery. *J Cardiothorac Vasc Anesth* 2018;32:2271–4.
- [52] Kunigo T, Murouchi T, Yamamoto S, et al. Injection volume and anesthetic effect in serratus plane block. *Reg Anesth Pain Med* 2017;42:737–40.
- [53] Ford DJ, Raj PP, Singh P, et al. Differential peripheral nerve block by local anesthetics in the cat. *Anesthesiology* 1984;60:28–33.
- [54] Capek S, Tubbs RS, Spinner RJ. Do cutaneous nerves cross the midline? *Clin Anat* 2015;28:96–100.
- [55] Ladak A, Tubbs RS, Spinner RJ. Mapping sensory nerve communications between peripheral nerve territories. *Clin Anat* 2014;27:681–90.
- [56] de la Cuadra-Fontaine JC, Altermatt FR. Continuous erector spinae plane (ESP) block: optimizing the analgesia technique. *J Cardiothorac Vasc Anesth* 2018;32:e2–3.
- *[57] Murouchi T, Yamakage M. Retrolaminar block: analgesic efficacy and safety evaluation. *J Anesth* 2016;30:1003–7.
- *[58] Versyck B, van Geffen GJ, Chin KJ. Analgesic efficacy of the Pecs II block: a systematic review and meta-analysis. *Anaesthesia* 2019 (in press).

- [59] O'Scanail P, Keane S, Wall V, et al. Single-shot pectoral plane (PECs I and PECs II) blocks versus continuous local anaesthetic infusion analgesia or both after non-ambulatory breast-cancer surgery: a prospective, randomised, double-blind trial. *Br J Anaesth* 2018;120:846–53.
- [60] Li N-L, Yu B-L, Hung C-F. Paravertebral block plus thoracic wall block versus paravertebral block Alone for analgesia of modified radical mastectomy: a retrospective cohort study. *PLoS One* 2016;11:e0166227.
- [61] Pawa A, Wight J, Onwochei DN, et al. Combined thoracic paravertebral and pectoral nerve blocks for breast surgery under sedation: a prospective observational case series. *Anaesthesia* 2018;73:438–43.
- [62] Ueshima H, Otake H. Addition of transversus thoracic muscle plane block to pectoral nerves block provides more effective perioperative pain relief than pectoral nerves block alone for breast cancer surgery. *Br J Anaesth* 2017;118:439–43.
- [63] Hetta DF, Rezk KM. Pectoralis-serratus interfascial plane block vs thoracic paravertebral block for unilateral radical mastectomy with axillary evacuation. *J Clin Anesth* 2016;34:91–7.
- [64] Gupta K, Srikanth K, Girdhar KK, et al. Analgesic efficacy of ultrasound-guided paravertebral block versus serratus plane block for modified radical mastectomy: a randomised, controlled trial. *Indian J Anaesth* 2017;61:381–6.
- [65] Pérez Herrero MA, López Álvarez S, Fadrique Fuentes A, et al. Quality of postoperative recovery after breast surgery. General anaesthesia combined with paravertebral versus serratus-intercostal block. *Rev Esp Anesthesiol Reanim* 2016;63:564–71.
- [66] Cros J, Sengès P, Kaprelian S, et al. Pectoral I block does not improve postoperative analgesia after breast cancer surgery: a randomized, double-blind, dual-centered controlled trial. *Reg Anesth Pain Med* 2018;43:596–604.
- [67] Goswami S, Kundra P, Bhattacharyya J. Pectoral nerve block 1 versus modified pectoral nerve block 2 for postoperative pain relief in patients undergoing modified radical mastectomy: a randomized clinical trial. *Br J Anaesth* 2017;119:830–5.
- [68] Abdallah FW, MacLean D, Madjdpour C, et al. Pectoralis and serratus fascial plane blocks each provide early analgesic benefits following ambulatory breast cancer surgery: a retrospective propensity-matched cohort study. *Anesth Analg* 2017;125:294–302.
- [69] Jüttner T, Werdehausen R, Hermanns H, et al. The paravertebral lamina technique: a new regional anesthesia approach for breast surgery. *J Clin Anesth* 2011;23:443–50.
- [70] Onishi E, Murakami M, Nishino R, et al. Analgesic effect of double-level retrolaminar paravertebral block for breast cancer surgery in the early postoperative period: a placebo-controlled, randomized clinical trial. *Tohoku J Exp Med* 2018;245:179–85.
- [71] Damjanovska M, Stopar Pintaric T, Cvetko E, et al. The ultrasound-guided retrolaminar block: volume-dependent injectate distribution. *J Pain Res* 2018;11:293–9.
- [72] Singh S, Chowdhary NK. Erector spinae plane block an effective block for post-operative analgesia in modified radical mastectomy. *Indian J Anaesth* 2018;62:148–50.
- [73] Kimachi PP, Martins EG, Peng P, et al. The erector spinae plane block provides complete surgical anesthesia in breast surgery: a case report. *A A Pract* 2018;11:186–8.
- [74] Ohgoshi Y, Ikeda T, Kurahashi K. Continuous erector spinae plane block provides effective perioperative analgesia for breast reconstruction using tissue expanders: a report of two cases. *J Clin Anesth* 2017;44:1–2.
- [75] Bonvicini D, Tagliapietra L, Giacomazzi A, et al. Bilateral ultrasound-guided erector spinae plane blocks in breast cancer and reconstruction surgery. *J Clin Anesth* 2017;44:3–4.
- [76] Gürkan Y, Aksu C, Kuş A, et al. Ultrasound guided erector spinae plane block reduces postoperative opioid consumption following breast surgery: a randomized controlled study. *J Clin Anesth* 2018;50:65–8.
- *[77] Altıparmak B, Korkmaz Toker M, Uysal Aİ, et al. Comparison of the effects of modified pectoral nerve block and erector spinae plane block on postoperative opioid consumption and pain scores of patients after radical mastectomy surgery: a prospective, randomized, controlled trial. *J Clin Anesth* 2018;54:61–5.
- [78] Adhikary SD, Pruet A, Forero M, et al. Erector spinae plane block as an alternative to epidural analgesia for post-operative analgesia following video-assisted thoracoscopic surgery: a case study and a literature review on the spread of local anaesthetic in the erector spinae plane. *Indian J Anaesth* 2018;62:75–8.
- [79] Forero M, Rajarathinam M, Adhikary S, et al. Continuous erector spinae plane block for rescue analgesia in thoracotomy after epidural failure: a case report. *A A Case Rep* 2017;8:254–6.
- [80] Kaplan I, Jiao Y, AuBuchon JD, et al. Continuous erector spinae plane catheter for analgesia after infant thoracotomy: a case report. *A A Pract* 2018;11:250–2.
- [81] Luis-Navarro JC, Seda-Guzmán M, Luis-Moreno C, et al. The erector spinae plane block in 4 cases of video-assisted thoracic surgery. *Rev Esp Anesthesiol Reanim* 2018;65:204–8.
- [82] Saad FS, El Baradie SY, Abdel Aliem MAW, et al. Ultrasound-guided serratus anterior plane block versus thoracic paravertebral block for perioperative analgesia in thoracotomy. *Saudi J Anaesth* 2018;12:565–70.
- [83] Park MH, Kim JA, Ahn HJ, et al. A randomised trial of serratus anterior plane block for analgesia after thoracoscopic surgery. *Anaesthesia* 2018;73:1260–4.
- *[84] Kim D-H, Oh YJ, Lee JG, et al. Efficacy of ultrasound-guided serratus plane block on postoperative quality of recovery and analgesia after video-assisted thoracic surgery: a randomized, triple-blind, placebo-controlled study. *Anesth Analg* 2018;126:1353–61.
- [85] Kunhabdulla NP, Agarwal A, Gaur A, et al. Serratus anterior plane block for multiple rib fractures. *Pain Physician* 2014;17:E651–3.
- [86] Hamilton DL, Manickam B. Erector spinae plane block for pain relief in rib fractures. *Br J Anaesth* 2017;118:474–5.
- *[87] Adhikary SD, Liu WM, Fuller E, et al. The effect of erector spinae plane (ESP) block on respiratory and analgesic outcomes in multiple rib fractures: a retrospective cohort study. *Anaesthesia* 2019;74:585–93.